

# Early Management of Hemi-Mandibulectomy Patient with Guide Plane Prosthesis : A Case Report

Gupta RK<sup>1</sup>, Soni S<sup>2</sup>, Nath A<sup>2</sup>, Bhasin R<sup>2</sup>

## Abstract

Occurrence of unilateral mandibular discontinuity, resulting due to trauma or surgery leads to mandibular deviation towards the defect side causing loss of occlusion on the unaffected side. Mandibular discontinuity leads to loss of balance and symmetry of mandibular function leading to altered mandibular movements. Mandibular deviation of unresected side due to involuntary action of contralateral musculature, particularly the medial pterygoid muscle and contraction of the cicatricial tissue on the resected side. Choice of surgical treatment modality depends on location and extent of tumours, various approaches can be Marginal, Segmental, Hemi-, Subtotal, or Total mandibulectomy. A definitive prosthesis can be given only after completion of healing process and acceptance of the osseous graft. Prosthodontic intervention is an important requirement for preventing the mandibular deviation during the initial healing period. The present case report describes early prosthodontic rehabilitation of a right side hemi-mandibulectomy patient with mandibular guide flange prosthesis. This prosthesis facilitates in guiding the mandible in normal position without deviation.

**Keywords :** Guide flange Prosthesis, Hemi-Mandibulectomy.

## Introduction

Neoplasms involving the mandible directly or indirectly requires surgical resection of the lesion and resection of the bone. It is simple to restore a small defect that is without any discontinuity of the bone with a prosthesis. Larger resections are more difficult to restore with a prosthesis, even though the continuity of the mandible is maintained.<sup>1-4</sup> As a general rule, the resection of a portion of the mandible without loss of mandibular continuity is usually not as debilitating as a resection that compromises mandibular continuity. Loss of mandibular

continuity causes deviation of remaining mandibular segment(s) towards the defect and rotation of the mandibular occlusal plane inferiorly. Reconstructive plastic surgery is done in cases of edentulous mandible to create a buccal or lingual sulcus depth that provides a favourable attached tissue foundation for an acceptable mandibular denture. Although immediate mandibular reconstruction is successful in restoring facial symmetry, arch alignment, and stable occlusion, still masticatory function often remains compromised. In 2007, a review of 32 articles described results of various mandibular

**Corresponding Author :** Dr. Rajiv Kumar Gupta, Reader, Department of Prosthodontics & Implantology, I.T.S Centre for Dental Studies and Research, Delhi-Meerut Road, Murad Nagar (201206), Ghaziabad, U.P

(M) +91-9999354667 E-mail : dent.rajiv@gmail.com

1. Reader, Department of Prosthodontics & Implantology, I.T.S Centre for Dental Studies and Research, Delhi-Meerut Road, Murad Nagar (201206), Ghaziabad, U.P

2. PG Student, Department of Prosthodontics & Implantology, I.T.S Centre for Dental Studies and Research, Delhi-Meerut Road, Murad Nagar (201206), Ghaziabad, U.P

reconstruction techniques and showed that functional outcomes were provided for only 4% of the 782 patients evaluated. Of all mandibular reconstructions Prosthetic rehabilitation was presented for only 16 patients (2%).<sup>5</sup> The longitudinal prospective study done by Garrett et al showed that 72% (33/46) of the subjects enrolled were able and willing to complete treatment with conventional prosthesis, and only 35% (16/46) completed implant-supported prostheses treatment.<sup>5,6</sup> Guide flange prosthesis (GFP) is a conventional mandibular prosthesis designed for the patient who is able to achieve a normal medio-lateral position of the mandible but is unable to repeat this position consistently. This case report describes early prosthodontic management (after initial healing period of the reconstructed mandible) of a patient who has undergone a right side hemimandibulectomy (from right condyle to right parasymphiseal region and modified neck resection) and reconstructed with apectoralis major myocutaneous (PMMC) flap.

### Case Report

A 51 year old male patient, a post operative right buccal mucosal carcinoma was referred to the Department of Prosthodontics, ITS Dental College, Muradnagar, Ghaziabad for prosthetic rehabilitation following a hemimandibulectomy & reconstruction with PMMC. A detailed case history revealed that the patient was diagnosed with the Squamous cell carcinoma of gingivo-buccal sulcus of right side which involved mandible. The patient had undergone Hemi-mandibulectomy (from the right condyle to the right parasymphiseal region) and the defect was immediately reconstructed with the PMMC flap, a month before presentation.

No intermaxillary fixation was done at the time of surgery. Extraoral examination showed facial asymmetry with mandibular deviation to the right side( Fig. 1a ).<sup>6,7</sup> Clinical examination revealed severe deviation of the mandible towards the right side, with lack of proper contact between the maxillary and the mandibular teeth anteriors on the left side. Intra-oral examination revealed thick, freely movable soft tissues with scar formation, loss of alveolar ridge and obliteration of buccal and lingual sulci in the right half of mandibular region. The deviation of mandible was observed towards the reconstructed (right) side (about 10 - 12 mm from midline on 30 mm of mouth opening) on opening due to the action of the normal left mandibular depressor muscles . The patient was able to achieve an appropriate medio-lateral position of the mandible with manual guidance but was unable to repeat this position consistently for adequate mastication. Intra oral examination showed missing teeth 15,16,17, 18, 26,27, 28, 35, 36, 38, 41, 42, 43, 44, 45, 46, 47 and 48 (Fig. 1b). The mandibular defect was classified as Cantor and Curtis Class IV i.e. resection of the lateral portion of the mandible with subsequent augmentation to restore form and function<sup>6</sup>

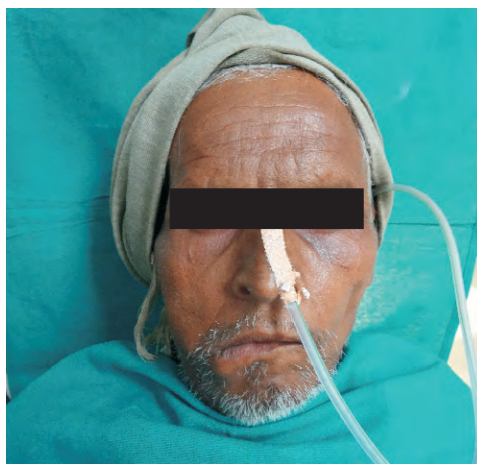

Fig 1(a): Extraoral view showing mandibular deviation

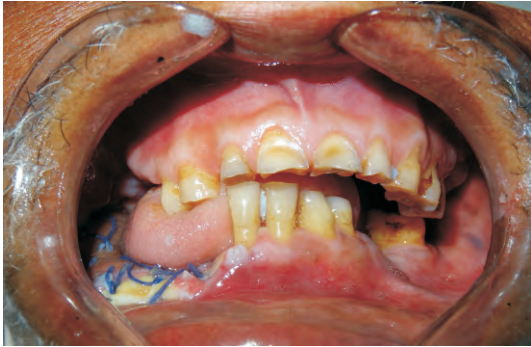

Fig 1(b): Intra-oral picture showing mandibular deviation.

A maxillary and mandibular impression was made by using irreversible hydrocolloid (Zelgan 2002, dentsply, ISO 9001), (Fig. 2a) using a modified stainless steel stock tray. The casts were poured with Type III dental stone (Gypstone Super hard dental Type III) (Fig. 2b). A maxillomandibular record was made by manually assisting the mandible into the centric occlusion. The maxillary and mandibular cast was mounted on a three point articulator.

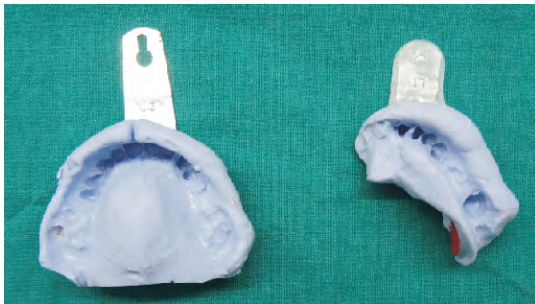


Fig 2(a): Maxillary and Mandibular impressions made using irreversible hydrocolloid.

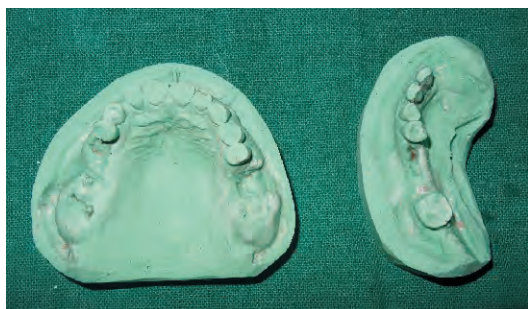

Fig 2(b): Maxillary and Mandibular casts poured using Type III Dental Stone.

The design (Fig. 3) included the guidance flange on the buccal side and the supporting flange on the lingual side. The retention was provided by the interdental clasp, engaging the incisors and the premolars using 21 gauge orthodontic wire (KC Smith and Co, Monmouth, UK). The guide flange extended superiorly and lingually on the buccal surface of the left incisors and the premolars, allowing the normal horizontal and vertical overlap of the left maxillary anterior teeth. The guide flange was sufficiently blocked out, so that it would not traumatize the left maxillary teeth and the gingiva when the patient closed his mouth and subsequently acrylized into the clear heat-polymerized acrylic resin (DPI Heat cure clear; Dental products of India, Mumbai, India) to make the GFP.

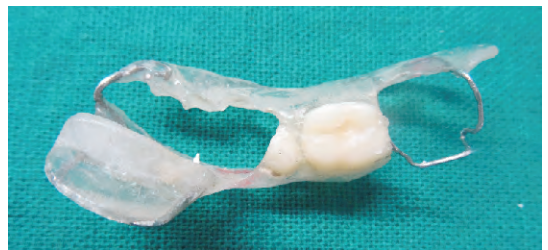

Fig.3: Guide Flange Prosthesis.

The prosthesis was finished, evaluated and inserted intraorally (Fig. 4). The GFP was tried in patient's mouth and the initial stability and retention was checked. The inclination of the guide-flange was adjusted by selectively trimming the teeth-contacting surface or adding the auto-polymerizing clear acrylic resin (DPI Cold cure clear; Dental products of India, Mumbai, India). A smooth gliding flange surface was developed intraorally to guide the mandible in a definite closing point (rather than the area) in occlusion. Care was taken to preserve the buccal-surface indentations of the opposing maxillary teeth which were guiding the mandible in a final

definite closing point during mastication. The flange height was adjusted in such a way that it guided the mandible from large opening position (in practical limits of the height of the buccal vestibule) to the maximum intercuspation in a smooth and unhindered path. The prosthesis was delivered and post-insertion instructions were given (Fig. 5).

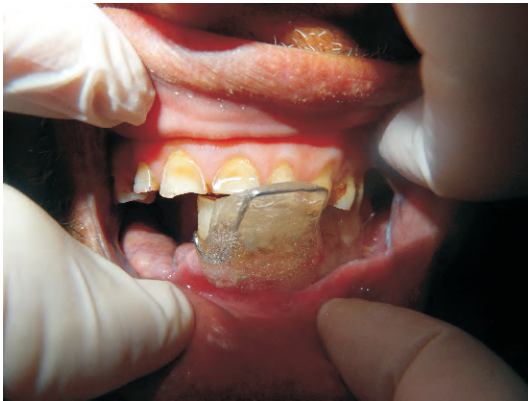

Fig.4: Intraoral view of Guide Flange Prosthesis in place.

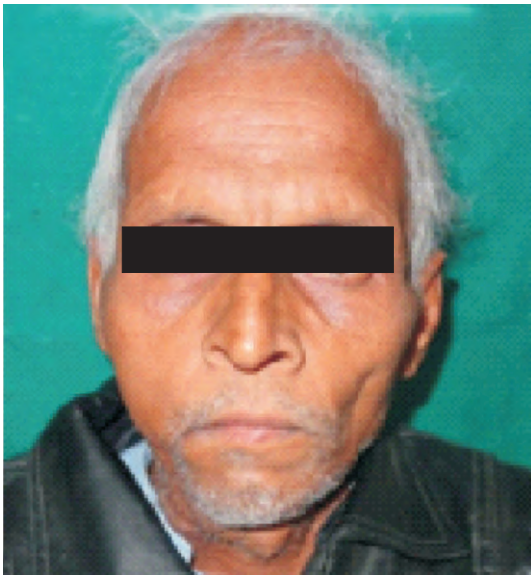

Fig.5: Absence of mandibular deviation post insertion.

The guide flange acted as a mechanical system which prevented the deviation of mandible towards the resected side. The patient was advised to use the guide flange device

throughout the day, except at night and during meals.

In such patients, definitive partial denture restorations are deferred until an acceptable maxilla-mandibular relationship is obtained or an end point in mandibular guidance therapy is attained. Guidance prosthesis and interim removable partial denture function as training appliances till a cast partial denture can be fabricated for the patient. Within 3 weeks, the mandible was guided to the correct occlusal position.

### Discussion

Loss of mandibular continuity results in deviation of remaining mandibular segment(s) towards the resected side and cause rotation of the mandibular occlusal plane inferiorly. This deviation towards the defect side occurs primarily because of the loss of tissue involved in the surgical resection.<sup>9,10</sup> A vertical extension from the buccal aspect of a mandibular prosthesis extends to contact the buccal surface of the opposing maxillary teeth. This extension aide in maintaining the mandible in the proper medio-lateral position, but little, if any, lateral movement is possible. In such cases immediate reconstruction is recommended to improve both facial symmetry and masticatory function. Although techniques for reconstructive surgery and prosthodontic rehabilitation have advanced, more than 50% of reconstructed head and neck cancer patients still suffer from impaired masticatory function. Recent development in facial reconstructive surgery and osseointegrated dental implants provide a treatment modality that may appropriately rehabilitate oral cancer patients for a healthy, productive life.

Successful mandibular guidance therapy depends mainly on the early beginning, the

nature of the surgical defect and the patient's co-operation. Mandibular guidance therapy begins when the immediate post-surgical sequelae have subsided, usually within 2 to 3 weeks after surgery. This kind of therapy is most successful in patients whose resection involves only bone structures and minimum resection of the tongue, the floor of the mouth and contiguous soft tissues. The presence of the teeth in both the arches is important for the effective guidance and the reprogramming of the mandibular movements.

The main purpose is to re-educate the mandibular muscles to re-establish an acceptable occlusal relationship (physiotherapeutic function) for the remaining hemimandible, so that the patient can control the opening and closing of the mandibular movements appropriately and consistently. Prosthetic management can be combined with an exercise program that can be started 2 weeks after the surgery for better results. On opening completely, the mandible can be displaced by hand as forcefully as possible towards the nonsurgical side. These movements help to reduce scar contracture, trismus, and improve maxilla-mandibular relationships.

### Conclusion

GFP is no different from that of any other removable prosthesis, the natural teeth and the residual alveolar ridge being the primary sources of support. Multiple retentive clasps in widely distributed areas of the arch would be the best approach, but the position of the teeth would determine the actual placement. Retentive elements should be no more rigid than required, but more rigidity with a decreasing number of teeth.<sup>11</sup> In the presented case retentive components were modified and incorporated into the prosthesis as a wire substructure.

The GFP can be regarded as a training type of prosthesis. If the patient can consistently repeat the medio-lateral position, the GFP can be discontinued. Some patient, however, may continue indefinitely with a guide flange, and the stress generated to the remaining teeth must then be carefully monitored.

### References

1. Beumer J, Curtis TA, Firtell DN. Maxillofacial rehabilitation: Prosthodontics and Surgical Considerations. St Louis, 1979, The CV Mosby Co, p 130-56.
2. Moore DJ, Mitchell DL. Rehabilitating edentulous hemimandibulectomy patients. *J Prosthet Dent* 1976; 35:202-6.
3. Robinson JE, Rubright WC. Use of a guide plane for maintaining the residual fragment in partial or hemimandibulectomy. *J Prosthet Dent* 1964; 14:992-9.
4. Taylor TD. Clinical maxillofacial prosthetics. Quintessence Publishing Co, Illinois, 1997. p. 155-88.
5. Shafer WG, Hine MK, Levy BM, Tomich CE. A textbook of oral pathology. 4ed. Philadelphia; WB Saunders; 2007. p. 86-229.
6. Cantor R, Curtis TA. Prosthetic managements of edentulous mandibulectomy patients. Part 1. Anatomic, physiologic and psychologic consideration. *J Prosthet Dent* 1971; 25:446-57.
7. Desjardins RP. Relating examination findings to treatment procedures. In: Laney WR, editor. Maxillofacial prosthetics. Littleton: PSG Publishing; 1979. pp. 69-114.
8. McGarry TJ et al. Classification system for partial edentulism. *J Prosthodont*. 2002; 11:181-91.
9. Taylor TD. Diagnostic considerations for prosthodontic rehabilitation of the mandibulectomy patient. In: Taylor TD, editor. Clinical maxillofacial prosthetics. Chicago; Quintessence Publishing; 2000. p. 155-70.
10. Olson ML, Shedd DP. Disability and rehabilitation in head and neck cancer patients after treatment. *Head Neck Surg*. 1978; 152-58.
11. Curtis DA, Plesh O, Miller AJ, Curtis TA, Sharma A, Schweitzer R, Hilsinger RL, Schour L, Singer M. A comparison of masticatory function in patients with or without reconstruction of the mandible. *Head Neck*. 1997; 19:287-96.