



Original Research Article

Cephalometric evaluation of vermillion height and lip area following 1st premolar extraction in various sagittal malocclusions in adult Solan population

Isha Aggarwal¹, Sahira Dadhwal^{1,*}, Sanjay Mittal¹, Merry Goyal¹, Avijit Avasthi¹¹Dept. of Dental, Bhojia Dental College and Hospital, Baddi, Himachal Pradesh, India

ARTICLE INFO

Article history:

Received 13-01-2023

Accepted 11-03-2023

Available online 28-03-2023

Keywords:

Vermillion height

Lip area

Bidental protrusion

Class II div 1

ABSTRACT

Introduction: Vertical thickness of the upper lip is an aesthetic determinant in a smiling face for both orthodontists.

Aim and Objectives: To evaluate the vermillion height and lip area in adult patients with various sagittal malocclusion groups following 1st premolar extraction.

Materials and Methods: Pre and post treatment lateral cephalograms of 50 adult patients aged between 17 to 21 years were taken. The sample was divided into 2 groups: Group I (Angles Class I Bidental protrusion) & Group II (Angles Class II div 1) with 25 subjects in each group. 2 angular and 10 linear measurements were recorded for both the groups.

Results: There were no significant differences in the vermillion height and upper lip area changes in group I, except for lower lip area. In group II significant difference were found in upper and lower lip area. When Group I and Group II were compared, only significant difference was found in lower lip area whereas vermillion height and upper lip area were found to be clinically non-significant.

Conclusion: Extraction of four premolars can be extremely successful in improving features of the smile for the patients who have undergone treatment for Class II division 1 malocclusion and Class I Bidental protrusion. This provides a stronger evidence-based rationale for this treatment modality.

This is an Open Access (OA) journal, and articles are distributed under the terms of the [Creative Commons Attribution-NonCommercial-ShareAlike 4.0 License](https://creativecommons.org/licenses/by-nc-sa/4.0/), which allows others to remix, tweak, and build upon the work non-commercially, as long as appropriate credit is given and the new creations are licensed under the identical terms.

For reprints contact: reprint@ipinnovative.com

1. Introduction

Orthodontists have long recognized that bicuspid extraction is often associated with changes in soft tissue profile. These changes can lead to significant improvements in profile and often justify extraction in patients who have no other indications. However, in some cases, it is also referred to as an 'orthodontic look' or 'arched' profile due to extraction of premolars. Although many studies have examined the relationship between incisor tooth movement and soft tissue profile changes, the extent of profile changes in premolar extraction treatments and whether these changes

are desirable or undesirable or there is surprisingly little direct information about this.¹

The goal of orthodontic treatment is not only to achieve functional occlusion, but also to improve facial and dental esthetics (Peck and Peck, 1970). Faces play an important position in conveying and interaction, which impacts all social relationships between human beings (Ferrario et al. 2003. Matoula and Pancherz, 2006. Vandergerd et al. 2007). Farkas (1994) discovered better vermillion upper lip peak at the lip relaxation position in aesthetically eye-catching man. Sforza et al. (2008) also mentioned that appealing kids have lips which can be large than common and distinguished.² Furthermore, recent studies have described that vermillion height plays a very

* Corresponding author.

E-mail address: 10sahiradadhwal@gmail.com (S. Dadhwal).

major role in determining smile aesthetics (McNamara et al., 2008). McNamara et al. (2008) concluded that the Upper lip's vertical thickness is a smile aesthetic factor for both orthodontists and laymen, and that the vertical thickness of the lower lip is a smile aesthetic factor for laymen. Therefore, the lips's vertical thickness was important in determining the appeal of a smile. Therefore, the ratio of thickness of upper lip to incisor ridges should be considered when arranging for orthodontic treatment.

According to certain theories, the vermilion height may be higher when both maxillae protrude because of the anterior teeth's labially angled position (McNamara et al., 2008). Premolar extractions can be used on these patients to straighten their profiles and encourage lip closure. In individuals with bimaxillary protrusion, Bill et al. (2005) found that extraction of four premolars straightened the lips. Consequently, this procedure can result in less vermilion in the front view. There have been studies on the connection between changes in the profile and anterior tooth recession (Oliver, 1982; Rains and Nanda, 1982; Drobocky and Smith, 1989; Bravo, 1994; Kusnoto and Kusnoto, 2001; Yasutomi et al., 2006).³ Hayashida et al., (2010) There have been reports of recession and profile alterations, but there has been no mention of a change in vermilion height or lip area as a result of the removal of four premolars.⁴

2. Aim and Objectives

To evaluate the vermilion height and lip area following 1st premolar extraction in various sagittal malocclusions in adult Solan population

3. Materials and Methods

Pre and post treatment lateral cephalograms of 50 adult patients aged between 17 to 21 years were taken. Each individual's basic information about name, age and history including that of previous orthodontic treatment was taken from the department of Orthodontics of Bhojia Dental College and hospital Baddi. Only the patients who satisfied the following selection criteria were involved in the study- Cases with Pre adjusted edgewise appliance therapy (PEA), Cases having first premolar extractions, Cases having Class I molar relationship bilaterally, Cases having Class II division 1 malocclusion and Lateral cephalograms of good quality. Exclusion Criteria included- Cases with Class III molar relationship bilaterally, Cases treated with surgical orthodontics and Non extraction cases.

The sample was divided into 2 groups: Group I (Angles Class I Bidental protrusion) & Group II (Angles Class II div 1) with 25 subjects in each group on the basis of Angles system of classification.

All the pre and post treatment lateral cephalograms obtained were traced by the same operator. All the landmarks and planes were identified and marked (Tables 2

Table 1: Grouping of sample

Group I	Group II
Angle's Class I (Bidental Protrusion) N=25	Angle's Class II division 1 N=25

and 3, Figures 1 and 2).

Table 2: Cephalometric landmarks

Landmarks	Definitions
Tip of the nose (Nt)	The most anterior point on the sagittal contour of the nose.
Subnasale (Sn)	Point at the junction of the columella and upper lip.
Sulcus Superior (Ss)	Point of greatest concavity in the midline between the labrale superior and subnasale.
Labrale superior (Ls)	The most anterior point on the convexity of the upper lip.
Labrale inferior (Li)	The most anterior point on the convexity of the lower lip.
Sulcus inferior (Si)	Point of greatest concavity in the midline between labrale inferior and soft tissue pogonion.
Soft tissue Pogonion (Pog')	The most anterior point of the soft tissue chin.

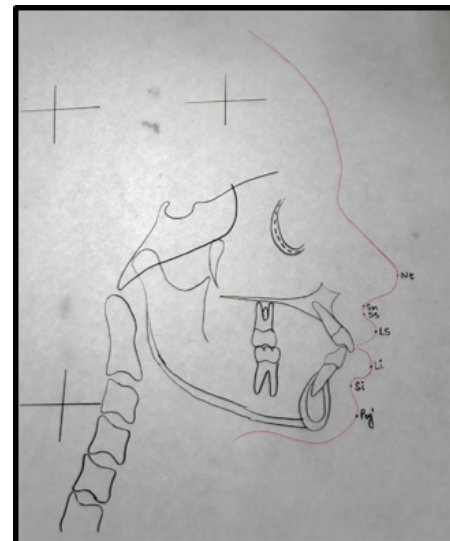


Fig. 1: Cephalometric landmarks

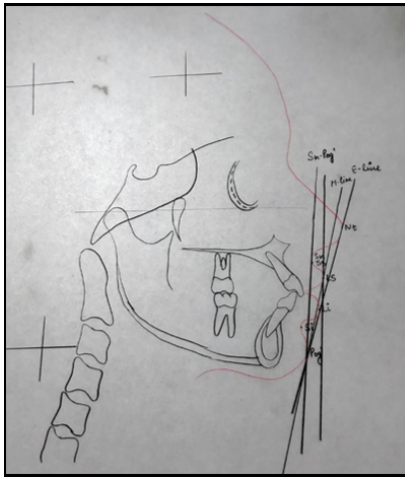
Various linear and angular parameters were measured to record the vermilion height and lip area (Tables 4 and 5, Figures 3 and 4)

3.1. Statistical analysis

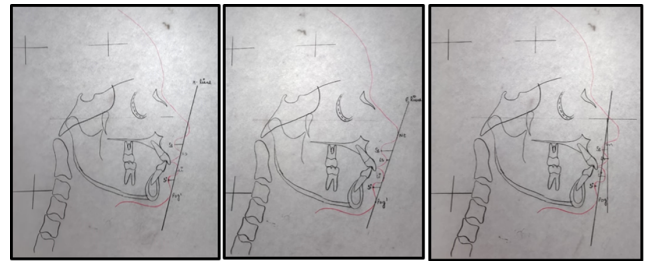
The values so obtained were subjected to statistical analysis using SPSS software. Wilcoxon signed-ranks tests were used to compare the pre-treatment and post-treatment

Table 3: Reference planes

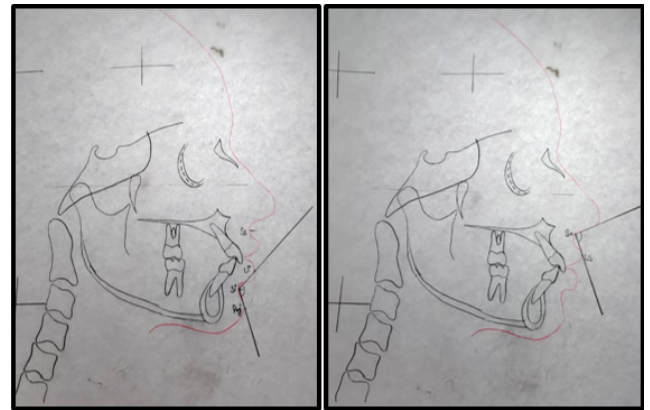
Planes	Definitions
E line	Drawn between nose tip and soft tissue pogonion.
Sn- Pog' Plane	Drawn between Subnasale and Soft tissue pogonion.
Ls perpendicular	Line tangent to Labrale superior and perpendicular to FH plane.
H line	Drawn tangent to soft tissue pogonion and labrale superior.

**Fig. 2:** Reference planes**Table 4:** Linear parameters

Parameters	Definitions
Ss to E line	Distance from Sulcus Superior to the Ricketts esthetic plane.
Ls to E line	Distance from Labrale Superior to the Ricketts esthetic plane.
Li to E line	Distance from Labrale inferior to the Ricketts esthetic plane.
Si to E line	Distance from Sulcus inferior to the Ricketts esthetic plane.
Ls to Sn – Pog'	Distance from Labrale Superior to the Burstone esthetic plane.
Li to Sn – Pog'	Distance from Labrale inferior to the Burstone esthetic plane.
Sulcus Superior Depth	Distance measured from Ss to a plane tangent to Ls and perpendicular to FH.
Ss to H line	Distance from Sulcus Superior to Holdaway harmony plane.
Li to H line	Distance from Labrale inferior to Holdaway harmony plane.
Si to H line	Distance from Sulcus inferior to Holdaway harmony plane.

**Fig. 3:** Linear parameters**Table 5:** Angular parameters

Parameters	Definitions
Labiomental angle	Formed by the intersection of a line drawn between Li and Si, and a line drawn between Si and Pog'.
Nasolabial angle	Formed by the intersection of a line originating at Sn, tangent to the lower border of the nose, a line from Sn to Ls.

**Fig. 4:** Angular parameters

values.

4. Result

Pre and Post treatment lateral cephalograms of 50 patients who underwent orthodontic treatment were included in the study. They were divided into 2 groups: Group I (Angle's Class I bidental protrusion, N=25) and Group II (Angle's Class II div 1 malocclusion, N=25). All the cephalograms were analysed by same operator. Vermillion height and lip area parameters were measured for both the groups. When pre and post treatment changes were compared in Group I (Angle's Class I bidental protrusion) significant differences were seen in Ls-Sn Pog' (p=0.00), Li-Sn Pog' (p=0.00) and Sulcus Superior Depth (p= 0.00) whereas on the contrary SS-E Line (p=0.08), LS-E line (p=0.03), Li-E line (p= 0.07), Si-E Line (p=0.19), Ss-H line (p=0.40), Si-H line (p=0.02), Li-H line (p=0.05), Labiomental Angle (p=0.24) and Nasolabial Angle (p= 0.19) were found to be

Table 6: Vermillion height and lip area changes in group I (angles class I bidental protrusion) using wilcoxon signed rank test

Parameters	Pre	Post	Z value	P value
SS-E Line	4.56 (\pm 2.77)	5.80 (\pm 2.17)	-1.718	0.08
LS-E line	1.56 (\pm 1.35)	2.64 (\pm 2.09)	-2.106	0.03
Li-E line	5.84 (\pm 2.32)	4.56 (\pm 2.59)	-1.801	0.07
Si-E Line	2.56 (\pm 2.43)	3.32 (\pm 2.47)	-1.297	0.19
Ls-Sn Pog'	6.60 (\pm 1.30)	4.72 (\pm 1.96)	-3.110	0.00*
Li-Sn Pog'	7.72 (\pm 2.30)	5.24 (\pm 3.64)	-3.070	0.00*
Sulcus Supeior Depth	2.40 (\pm 1.25)	3.44 (\pm 1.60)	-2.946	0.00*
Ss-H line	3.44 (\pm 2.69)	4.00 (\pm 2.19)	-0.831	0.40
Si-H line	2.20(\pm 1.65)	3.68 (\pm 2.64)	-2.300	0.02
Li-H line	4.84(\pm 2.85)	3.68 (\pm 1.97)	-1.947	0.05
Labiomental Angle	133.68 (\pm 27.50)	133.72 (\pm 12.68)	-1.172	0.24
Nasolabial Angle	102.16 (\pm 8.65)	105.96(\pm 10.08)	-1.294	0.19

clinically non-significant.

When pre and post treatment changes were compared in Group II (Angles's Class II div 1) significant changes were seen in Li-H line ($p=0.00$) whereas on the contrary Ss-E Line ($p=0.84$), Ls-E line ($p=0.19$), Li-E line ($p=0.09$), Si-E Line ($p=0.07$), Ls-Sn Pog' ($p=0.03$), Li-Sn Pog' (p value = 0.05), Ss-H line ($p=0.05$), Si-H line ($p=0.50$), Li-H line ($p=0.05$), sulcus superior depth ($p=0.65$), Labiomental Angle ($p=0.35$) and Nasolabial Angle ($p=0.21$) were found to be clinically non significant.

When Vermillion Height and Lip Area changes were compared between Group I (Angle's Class I bidental protrusion) and Group II (Angles's Class II div 1) significant changes were seen in Li-E line ($p=0.02$) and Li-Sn Pog' (p value= 0.00) whereas on the contrary Ss-E Line ($p=0.96$), Ls-E line ($p=0.62$), Si-E Line ($p=0.65$), Ls-Sn Pog' ($p=0.41$), Sulcus superior depth (p value= 0.54), Ss-H line ($p=0.58$), Si-H line ($p=0.51$), Li-H line ($p=0.35$), Labiomental Angle ($p=0.35$) and Nasolabial Angle ($p=0.41$) were found to be clinically non-significant.

5. Discussion

One of the most critical issues that both orthodontists and their patients worry about is facial aesthetics. When interacting with another person, people tend to pay particular attention to their eyes and mouth (Evans et al., 2005).⁵ Face is therefore crucial for contact and communication in human society. Because malocclusion, tooth stability, and facial esthetics are influenced in part by the total mass, position in space, and general activity of the soft tissue structures, the orthodontist should consider soft tissue morphology and the posture of the lips. Till date, According to studies, the lateral view antero-posterior evaluation of the aesthetic characteristics of lip position (Farrow et al., 1993; Ioi et al., 2005; McKoy-White et al., 2006; Chan et al., 2008).^{6,7} Orthodontic treatment not only produces changes in dental component but also indirectly alters the soft-tissue profile of the patient Swati Kapoor et al. (2022), Sundareswaran S, Vijayan R. (2019). Patients

frequently assess their facial aesthetics in the mirror, so it is necessary to study morphological lip alterations from the frontal aspect.⁸ Burstone (1967) in Class II division 1 case in which there is a significant overjet, the closed lip position is interpreted as that position in which light contact exists between the lower lip and the maxillary incisor. If lip posture is to be evaluated, it is well to standardize the vertical dimension of the jaws. The recording of lip posture is further complicated by the fact that we are dealing with muscles innervated by the seventh cranial nerve.⁹ The seventh nerve is closely associated with the autonomic nervous system and has connections at a higher level with the hypothalamus, which means that emotional states can strongly influence the contraction or lack of contraction of the muscle fibers of the lip. With care, however, the investigator or clinician can obtain records of the relaxed-lip position that are relatively reproducible. Extraction might have a smaller impact on the facial profile if the incisors are retracted less during treatment (i.e. if extraction spaces are closed through mesial movement of the posterior teeth or if extractions are used to accommodate blocked-out teeth) Dimitrios Konstantonis (2018).¹⁰

Jacobson (1957) reported that a normal distance for the incisors from both the upper and lower lip is 7.0 and 2.0 mm behind the E-plane, respectively. Keating (1985) found that the lower lip is 6.0 mm ahead of the E-plane in Caucasian patients with bid protrusion. It is impossible to determine or readily put into a formula the specific aspects of the change in soft tissue profile brought on by tooth movement. The arrangement of the soft tissues in the face might vary just as much as malocclusion itself. Mishra et al (2020) compared post treatment lip profile changes in patients with Class II Division 1 malocclusion and skeletal Class I malocclusion of varied growth patterns treated with maxillary premolar extractions and found out that during the course of active therapy, there was a significant link between upper lip thickening and incisor retraction. The position of the maxillary incisor and the vertical thickness of the upper lip were found to be positively correlated by Gupta V et al.

Table 7: Vermillion height and lip area changes in Group II Angles Class II div 1 using wilcoxon signed rank test

Parameters	Pre	Post	Z value	P value
Ss – E Line	6.44 (±1.98)	6.72 (±2.93)	-.199	0.84
Ls-E line	2.28 (±1.27)	1.72 (±1.40)	-1.279	0.19
Li-E line	3.16 (±2.37)	4.24 (±2.64)	-1.685	0.09
Si –E Line	4.32 (±1.81)	3.52 (±1.73)	-1.756	0.07
Ls-Sn Pog'	6.28 (±1.72)	5.16 (± 1.97)	-2.085	0.03
Li-Sn Pog'	3.04 (±1.20)	3.88 (±1.42)	-1.960	0.05
Sulcus Supeior Depth	4.08 (±1.52)	3.80 (±1.50)	-.448	0.65
Ss-H line	5.76 (±1.50)	4.76 (±2.02)	-1.886	0.05
Si-H line	1.96 (±1.09)	1.84 (±1.99)	-.664	0.50
Li-H line	6.08(±1.11)	4.92(±1.57)	-2.688	0.00*
Labiomental Angle	141.88(±11.60)	138.88(±6.36)	-.929	0.35
NasioLabial Angle	101.04(±12.38)	103.88(±10.05)	-1.238	0.21

Table 8: Comparison of vermilion height and lip area changes between class 1 Bidental Protrusion and Class 2 Div 1 occlusion using wilcoxon signed rank test

Parameters	Group I (Class I)	Group II (Class 2 Div 1)	Z Value	P Value
SS-E Line	2.76 (±2.20)	2.68 (±1.84)	-.048	0.96
LS-E line	1.96 (± 1.69)	1.76 (±1.12)	-.493	0.62
Li-E line	2.80 (±2.06)	1.76 (±1.12)	-2.292	0.02*
Si-E Line	2.04 (±1.83)	2.00 (±1.41)	-.449	0.65
Ls- Sn Pog'	2.48(±1.87)	2.16 (±2.01)	-.809	0.41
Li-Sn Pog'	3.60 (±2.19)	1.72 (±1.06)	-2.828	0.00*
Sulcus Supeior Depth	1.44 (±1.15)	1.72 (±1.56)	-.611	0.54
Ss-H line	2.16 (±2.03)	2.36 (±1.38)	-.548	0.58
Si-H line	2.36 (±2.07)	1.56(±1.35)	-1.417	0.15
Li-H line	2.44 (±2.00)	1.80(± 1.15)	-.922	0.35
Labiomental Angle	10.68 (±8.97)	12.44(± 7.84)	-.744	0.45
NasioLabial Angle	9.24 (±9.76)	11.48(±9.09)	-1.001	0.31

(2021) as well.¹¹ The present study is done to evaluate the vermilion height and lip area in adult patients with various malocclusions following 1st premolar extraction. 50 Pre and post treatment lateral cephalograms of adult patients aged between 17 to 21 years were included. The sample was then divided into 2 groups: Group I (Angles Class I Bidental protrusion, N=25) & Group II (Angles Class II div 1, N=25).

5.1. Angles Class I

When pre and post treatment changes were compared in Angles Class I bidental protrusion upper and lower lip to E line, and H line, Labiomental angle and Nasolabial angle were found to be clinically non-significant with increase in post treatment values. This might be due to the facial soft tissue configuration and the lip posture itself. The soft-tissue profile is following changes of the lips and can be solution for prediction of stability after orthodontic therapy. Joshi et al (2015) When the lower lip was compared to the H line, it was discovered that the Angle's Class I (bidental protrusion) lower lip was protruding more than the norms. From a clinical perspective, it is easier to determine the position of the lips if the reference line is placed closer

anteroposteriorly to the lips. The E and the H lines are more dependable in this regard. The E line and the H line may have less regularity because they pass through the nose and the UL, respectively.¹² Zierhut et al(1999) found that soft-tissue convexity was reducing with the treatment and this reduce was progressing with time regardless therapy. Burstone (1967) brought to light the importance of the relaxed lip posture when evaluating the changes from pre- to post-treatment lip positions. Suntornlohanakul S(2018), Jongphairotkhosit J, Rumphai (2018), Oliver (2005) stated that patients with thin lips or a high lip strain displayed a significant correlation between incisor retraction and lip retraction, whereas patients with thick lips or low lip strain displayed no such correlation. Vermillion height change was shown to be non-significant, which indicates that the ideal vermilion height would be one of the treatment goals for orthodontic treatment; nevertheless, the ideal vermilion height values require further research.¹³ Divya Mishra, Madhumitha Natarajan, and Arun S. Urala(2020) This finding was associated with a change in incisor angle and palatal tilt, but there was no consistent relationship with the horizontal movement of the incisor edge.¹⁴ On the contrary Lower lip to Sn pog' and Sulcus superior depth were found

to be clinically significant with increase in post treatment values which means there is change in upper and lower lip area. This seems consistent with Hasstedt's (1976) work and is shown by his strong correlation of upper lip thickening with incisor retraction during the period of active treatment; this relationship disappears when the retention and post retention periods are included. The clinical observation that flared incisors tend to roll the upper and lower lips out, exposing more of the mucocutaneous lip and enlarging the vermilion height and lip area is supported by this research (McNamara et al., 2008). The position of the maxillary incisor and the vertical thickness of the top lip were found to be positively correlated by McNamara et al. (2008). For patients with bidental protrusion, improving their profiles through posterior migration of their anterior teeth is crucial. (Shimomura et al., 2011).¹⁵ The protrusion of lips was associated with significant labial inclination of lower incisors. Another possible reason may be less prominent nasal tips and steeper nasal bridge. The relationship between lips and the aesthetic line was examined by Forsberg and Odernick(1979) in individuals aged 8 and 25 years with Class I - ANB angle, Ls:EL and Li:EL were measured. Examining the changes of soft tissue (nose, lips and chin), Prahl-Andersen et al(1995) found that growth of the nose is connected with skeletal growth. Kasai(1994) reported the relationships between the hard tissue structures and the soft tissue profile in the static state, that is, a small ANB angle is associated with a smaller pogonion thickness and a relatively thick upper lip whereas a relatively forward position of lower incisors and a larger lower-facial height is associated with thicker soft tissue at point B. In a previous study, Bills et al. (2005) came to the conclusion that individuals with bidental protrusion might have their lips straightened by having four premolars extracted. Therefore, from a frontal perspective, this therapeutic approach might lead to a reduction in vermilion height. While several research (Oliver, 1982; Rains and Nanda, 1982; Drobocky and Smith, 1989; Bravo, 1994; Kusnoto and Kusnoto, 2001; Yasutomi et al., 2006; Hayashida et al., 2010) revealed that the removal of four premolars had no effect on the vermilion height or lip area.¹¹

5.2. Angles Class II div 1

When pre and post treatment changes were compared in Angles class II Div 1 upper and lower lip to E line, H line and Sn-pog', Sulcus superior depth, Labiomental angle and Nasiolabial angle were found to be clinically non-significant with increase in post treatment values whereas lower lip to H line was found to be clinically significant with increase in post treatment values which means there are changes in lower lip area after orthodontic treatment, reason being bringing the protrusive lips into the ideal range makes the excessive opening of the nasolabial angle or an increase in distance from sulcus inferior to the esthetic plane.¹³ Irena

Gavrilovic (2006) The upper lip was found to be closer to the esthetic line (E line) and lower lip to be further from the esthetic line (E line) than in patients with normal occlusion. Lower incisors' modest proclination, which was done to relieve crowding in the NE group, caused a decrease in the linear distance between them and the labral inferius, which caused the prominence of the lower lip to grow. Yuko Oomori et al. (2020) Adequate retraction of the upper incisors in the maxillary protrusion with excessive overjet may retract not only the upper vermilion lip but also the lower one, suggesting that morphological changes in the lower lip are affected by the positioning of the upper incisors. In addition, the patterns of morphological changes differed the patterns of morphological changes differed between the upper and lower vermilion lips, with a large proportion of rotational change toward the mucous membrane in the upper vermilion lip and with a pattern of change resembling horizontal displacement in the lower vermilion lip.¹⁴ In their investigation, Saelens, Smit, and Finnöy et al. (1994) discovered that the nasolabial angle was higher in the extraction group. With an average of about 0.6:1, the lower incisor-lower lip ratios are significantly more closely grouped than the upper incisor-upper lip ratios. This suggests that, on average, the lower lip recedes by 1 mm for every 0.6 mm that the lower incisors recede. Rudee (1964) report that the basic upper lip thickness, measured at the base of the alveolus at a level below the area where the nasal structures influence the drape of the lip, is thought to influence the relationship of osseous changes to soft tissue changes in this region of the midface. In patients with thin lips the correlation between osseous and soft-tissue changes was significant. Drobocky and Smith(1989) Dental retraction allowed the vermilion border to retract. West (1987) implied that maxillary lip thickness and lip strain may play a significant role in the prediction of soft-tissue changes subsequent to orthodontic retraction of maxillary incisors. Basic upper lip thickness, measured at the base of the alveolus at a level below the area where the nasal structures influence the drape of the lip, is thought to influence the relationship of osseous changes to soft tissue changes.¹⁶

5.3. Comparison between Angles Class I and Angles Class II div 1

When Angle's Class I Bidental protrusion and Angle's Class II div 1 changes were compared upper lip to E line, H line and Sn Pog', Sulcus superior depth, Labiomental angle and Nasiolabial angle were found to be clinically non-significant whereas Lower lip to E line and Sn pog' were found to be significant. Post-treatment values of vermilion height and lip area in Angle's Class I (bidental protrusion) were significantly greater than those of the Angle's Class II div 1 for both upper and lower lips, this might be because bidental protrusion have effects on both upper and lower lip where

protrusion of lips is seen whereas in Class II div 1 upper lip is affected¹⁴. In circumstances when there is initially lip compression, lip thickness increases when the incisors are retracted before the lip repositions. RM Alkadhi(2019) Such a link has been proven by Rudee (1964), Huggins and McBride (1975), and Holdaway (1983). Hershey (1972), Wisth (1974), and other researchers have also demonstrated that the degree of soft tissue reaction varies with incisor retraction, lip strain and shape, age, and sex. According to Rains and Nanda (1990), the movement of the lower lip, the mandibular rotation, and the upper and lower incisors were all related to the upper lip response. According to Joshi et al. (2015), the E line and H line are less accurate at determining sagittal lip location in skeletal malocclusions. Divya Mishra, Madhumitha Natarajan, and Arun S. Urala(2020) Soft tissue changes (lip strain, Sn to H line, lower lip to H line, upper lip to E line, lower lip to E line values) were similar to patients with a skeletal Class I relationship, who possessed an esthetically pleasing profile or were considered beautiful. Burstone(1958), Hershey (1972), and Xu et al.(2006) proposed that the perioral soft-tissue may be self-supporting and factors other than dental movement may cause wide variability of individual response. The distance between the upper and lower lips to the esthetic line increased highly significantly in all our groups during treatment, meaning that the lip profile became more concave. The space available for the tongue is reduced as a result of front teeth retraction. The anterior teeth may relapse as a result of these alterations. The stable placements of both hard and soft tissues must therefore be assessed again on these individuals following the retention period.¹⁷

The current study showed that when the four premolars were extracted, the vermilion height and lip area post-treatment values increased. Modifications in the original skeletal and soft tissue variables may have predicted the decreased values of vermilion height and lip area. We discovered that meticulous observation of each person while analysing unique soft tissue patterns is required in order to accurately forecast post-treatment changes.

6. Conclusion

Extraction of four premolars can be extremely successful in improving features of the smile like lip area and vermilion height for the patients who have undergone treatment for Class II division 1 malocclusion and Class I Bidental protrusion. This provides a stronger evidence-based rationale for this treatment modality.

7. Conflict of Interest

None.

8. Source of Funding


None.


References


1. Bravo L. Soft tissue facial profile changes after orthodontic treatment with four premolars extracted. *Angle Orthodontist*. 1994;64(1):31–42. doi:10.1043/0003-3219(1994)064<0031:STFPCA>2.0.CO;2.
2. Burstone C. Lip posture and its significance in treatment planning. *Am J Orthod*. 1967;53(4):262–84. doi:10.1016/0002-9416(67)90022-x.
3. Drobocky OB, Smith R. Changes in facial profile during orthodontic treatment with extraction of four first premolars. *Am J Orthod Dentofacial Orthop*. 1989;95(3):220–30. doi:10.1016/0889-5406(89)90052-8.
4. Farrow AL, Zarrinnia K, Azizi K. Bimaxillary protrusion in black Americans—an esthetic evaluation and the treatment considerations. *Am J Orthod Dentofacial Orthop*. 1993;104(3):240–50. doi:10.1016/S0889-5406(05)81725-1.
5. Trisnawaty N, Ioi H, Kitahara T, Suzuki A, Takahashi I. Effects of extraction of four premolars on vermilion height and lip area in patients with bimaxillary protrusion. *Eur J Orthod*. 2013;35(4):521–8. doi:10.1093/ejo/cjs035.
6. Hayashida H, Ioi H, Nakata S, Takahashi I, Counts A. Effects of retraction of anterior teeth and initial soft tissue variables on lip changes in Japanese adults. *Eur J Orthod*. 2010;33(4):419–426.
7. Ioi H, Nakata S, Nakasima A, Counts A. Anteroposterior lip positions of the most-favored Japanese facial profiles. *Am J Orthod Dentofacial Orthop*. 2005;128(2):206–11. doi:10.1016/j.ajodo.2004.04.030.
8. Islam R, Kitahara T, Naher L, Hara A, Nakashima A. Lip morphological changes in orthodontic treatment: class II division 1 malocclusion and normal occlusion at rest and smiling. *Angle Orthod*. 2009;79(2):257–64. doi:10.2319/030308-125.1.
9. Kusnoto J, Kusnoto H. The effect of anterior tooth retraction on lip position of orthodontically treated adult Indonesians. *Am J Orthod Dentofacial Orthop*. 2001;120(3):304–7. doi:10.1067/mod.2001.116089.
10. Oliver B. The influence of lip thickness and strain on upper lip response retraction. *Am J Orthod*. 1982;82(2):141–9.
11. Peck H, Peck S. A concept of facial esthetics. *Angle Orthodontist*. 1970;40(4):284–318. doi:10.1043/0003-3219(1970)040<0284:ACOFE>2.0.CO;2.
12. Rains MD, Nanda R. Soft-tissue changes associated with maxillary incisor retraction. *Am J Orthod*. 1982;81(6):481–8. doi:10.1016/0002-9416(82)90427-4.
13. Ricketts R. A foundation for cephalometric communication. *Am J Orthod*. 1960;46:331–7.
14. Sforza C, Laino A, 'alessio RD, Grandi G, Tartaglia GM, Ferrario V, et al. Soft-tissue facial characteristics of attractive and normal adolescent boys and girls. *Angle Orthodontist*. 2008;78(5):799–807. doi:10.2319/091207-431.1.
15. Shimomura T, Ioi H, Nakata S, Counts A. Evaluation of well-balanced lip position by Japanese orthodontic patients. *Am J Orthod Dentofacial Orthop*. 2011;139(4):291–7. doi:10.1016/j.ajodo.2009.06.030.
16. Geld PD, Oosterveld P, Van Heck G, Kuijpers-Jagtman AM. Smile attractiveness. Self-perception and influence on personality. *Angle Orthod*. 2007;77(5):759–65. doi:10.2319/082606-349.
17. Yasutomi H, Ioi H, Nakata S, Nakashima A, Counts A. Effects of retraction of anterior teeth on horizontal and vertical lip positions in Japanese adults with the bimaxillary dentoalveolar protrusion. *Orthodontic Waves*. 2006;65(4):141–9. doi:10.1016/j.odw.2006.09.001.


Author biography

Isha Aggarwal, Professor  <https://orcid.org/0000-0002-7030-2579>

Sahira Dadhwal, Post Graduate Student  <https://orcid.org/0000-0002-2811-8989>

Sanjay Mittal, Professor  <https://orcid.org/0000-0002-7125-0424>

Merry Goyal, Reader  <https://orcid.org/0000-0002-7098-5496>

Avijit Avasthi, Reader  <https://orcid.org/0000-0002-2600-5411>

Cite this article: Aggarwal I, Dadhwal S, Mittal S, Goyal M, Avasthi A. Cephalometric evaluation of vermillion height and lip area following 1st premolar extraction in various sagittal malocclusions in adult Solan population. *J Dent Spec* 2023;11(1):54-61.