



## Case Report

# Horizontal maxillary ridge augmentation with ridge split procedure and simultaneous implant placement: A case report

Abir Sarkar<sup>1</sup>, Pramod K Chahar<sup>2</sup>, Vaibhav Jain<sup>3,\*</sup>, Vishvnaathe Udayshankar<sup>4</sup>

<sup>1</sup>Dept. of Prosthodontics and Crown & Bridge, Military Dental Centre, Meerut, Uttar Pradesh, India

<sup>2</sup>Dept. of Prosthodontics and Crown & Bridge, Military Dental Centre, Roorkee, Uttarakhand, India

<sup>3</sup>Dept. of Prosthodontics and Crown & Bridge, INDC Danteshwari, Mumbai, Maharashtra, India

<sup>4</sup>Dept. of Prosthodontics and Crown & Bridge, Military Dental Centre, Wellington, Tamil Nadu, India



## ARTICLE INFO

### Article history:

Received 16-06-2021

Accepted 03-09-2021

Available online 09-10-2021

### Keywords:

Ridge split

Ridge Augmentation

Esthetic rehabilitation

Prosthetic driven implantology

## ABSTRACT

Treatment of edentulous maxillary anterior region with horizontal ridge atrophy presents a clinical situation in which the placement of endosseous implants might be complex or sometimes impossible without a ridge augmentation procedure. This case report presents management of horizontally deficient maxillary anterior ridge with ridge split procedure using piezotome and simultaneous implant placement. In contrast to other ridge augmentation techniques, ridge splitting allows for immediate implant placement following surgery reducing the overall treatment time and eradicates the possible morbidity from a second surgical site.

This is an Open Access (OA) journal, and articles are distributed under the terms of the [Creative Commons Attribution-NonCommercial-ShareAlike 4.0 License](https://creativecommons.org/licenses/by-nc-sa/4.0/), which allows others to remix, tweak, and build upon the work non-commercially, as long as appropriate credit is given and the new creations are licensed under the identical terms.

For reprints contact: [reprint@ipinnovative.com](mailto:reprint@ipinnovative.com)

## 1. Introduction

Implant dentistry has emerged as a prosthetically driven surgical – restorative discipline in recent past. In order to properly restore endosseously placed implants, they have to be inserted into the bone in a restoratively driven position, identical or close to where the natural teeth used to be, even if bone was no longer available in the area. Atrophic edentulous jaws can represent a significant challenge to this concept. The horizontal and vertical ridge resorption occurs at differential rates that vary among individuals and at different sites in the same person. An estimated resorption of 40-60% of bone height and width occurs in initial 2-3 years after tooth loss.<sup>1</sup> The greatest bone resorption occurs in the horizontal plane, which leads to considerable loss of alveolar width.<sup>2</sup> Several management protocols have been proposed for horizontal defects such as Onlay (veneer) extraoral (hip, rib,

calvarium).<sup>3</sup> and intraoral (chin, ramus, posterior mandible, zygomatic buttress, maxillary tuberosity)<sup>4</sup> block bone graft, guided bone regeneration,<sup>5</sup> ridge splitting procedures<sup>6</sup> and alveolar distraction osteogenesis<sup>7</sup> in the literature.

The ridge split procedure consists of splitting the facial or buccal cortical plate from the lingual or palatal and subsequent expansion with osteotomes<sup>8</sup> and is generally recommended for use in the maxillary esthetic zone and posterior mandible. The ridge-split technique has had a success rate of 98% to 100% according to some studies.<sup>7</sup>

## 2. Case Report

A 30 years old male patient reported to the Department of Prosthodontics with a chief complaint of missing upper front teeth (Figure 1). He gave an history of trauma to the region due to a road traffic accident 3 years ago and following which the 11 and 21 teeth have been extracted. The patient was systemically healthy. On intraoral examination horizontal alveolar defect was noticed in relation to the edentulous region. A complete

\* Corresponding author.

E-mail address: [drvaibhav40@gmail.com](mailto:drvaibhav40@gmail.com) (V. Jain).

case history with preoperative procedures including oral prophylaxis was performed. Diagnostic impression with irreversible hydrocolloid was made and diagnostic casts were obtained. After an orientation jaw relation record casts were mounted in centric relation on a semi adjustable articulator. This was followed by investigations including routine blood screening, conventional orthopantomogram (OPG) and Cone beam computed tomogram (CBCT) (Figure 2). Corroborating the clinical findings with the radiological investigation data, a diagnosis of Kennedy's class IV partially edentulous arch with Siebert's class I ridge defect was determined.

A diagnostic mockup was done and various treatment options available were discussed with the patient and they were compared in the light of available clinical, radiological results. Implant retained fixed prosthesis (FPI) was decided subsequently as the treatment option. Detailed examination of CBCT revealed. That the maxillary anterior edentulous region was deficient in width for a successful rehabilitation with endosseous implants. Ridge split procedure was chosen to augment the region for successful implant placement.

	11 region	21 region
<b>Bone height</b>	15.6 mm	15.6 mm
<b>Bone width</b>	4.4 mm	3.2 mm
<b>Bone length</b>	8.8 mm	8.9 mm
<b>Bone angulation</b>	60 <sup>0</sup>	64.8 <sup>0</sup>
<b>Crown height space</b>	9 mm	10 mm
<b>Bone density</b>	1036 HU	1058 HU

After administration of local anesthesia (2% lidocaine with 1:200,000 adrenaline) a para-crestal incision was given to elevate a full thickness mucoperiosteal flap. Initially, mid-crestal cut was placed using piezotome. After that two lateral cortical cut were placed on either side of the edentulous span. The lateral cuts were then connected with the horizontal crestal cut to allow for smooth uniform depth with rounded corners. Subsequently graduated osteotomes of increasing thickness were used with gentle tapping with a mallet to gradually expand the ridge and mobilize the buccal cortical bone facially (Figure 3). All attempts to avoid fracture of the buccal and palatal cortical bone were taken during mobilization of the cortical bone by providing adequate bi digital support and flat end of the osteotome was laced against the palatal side. Furthermore, the ridge was carefully expanded to prevent fenestration and off-axis loading after implant placement. Osteotomy sites were prepared in relation to 11 and 21 region to place two implants of dimensions 3.75 mm × 13 mm using pilot drill of 2 mm followed by 2.8 mm, 3.2 mm and 3.65 mm diameter drill. Self-tap implants were placed in the osteotomy bed (Figure 4). The interpositional space between the cortical plates was filled with particulate grafts – Sybografit (composite). A reservable bio-membrane was placed to protect the graft and the flap was closely

approximated using 3-0 vicryl sutures. The postoperative instructions were given. Antibiotics and analgesics were prescribed and 0.2% chlorhexidine rinse was advised to be used every 3 h for 1 week and twice daily for following 2 weeks postoperatively. The suture removal was done on the 15th day after surgery. A Provisional restoration in the form of resin retained FDP was fabricated and luted for esthetics. The ridge splitting technique performed in this case allowed a definite gain in width uniformly throughout the edentulous span. The postoperative OPG taken on the 15th day after surgery showed the healing phase bone following the implant placement. The follow-up CBCT was taken on the 15th day showing ridge expansion of 7.2 mm, 6.4 mm, respectively at implant site 11 and 21 (Figure 5). The final cement retained prosthesis is luted after 3 months following implant placement (Figure 6).

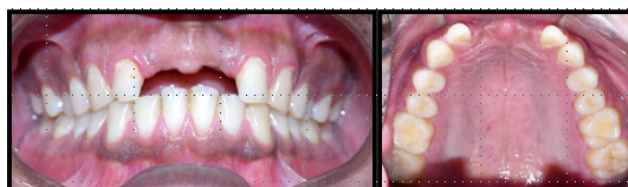

Fig. 1:

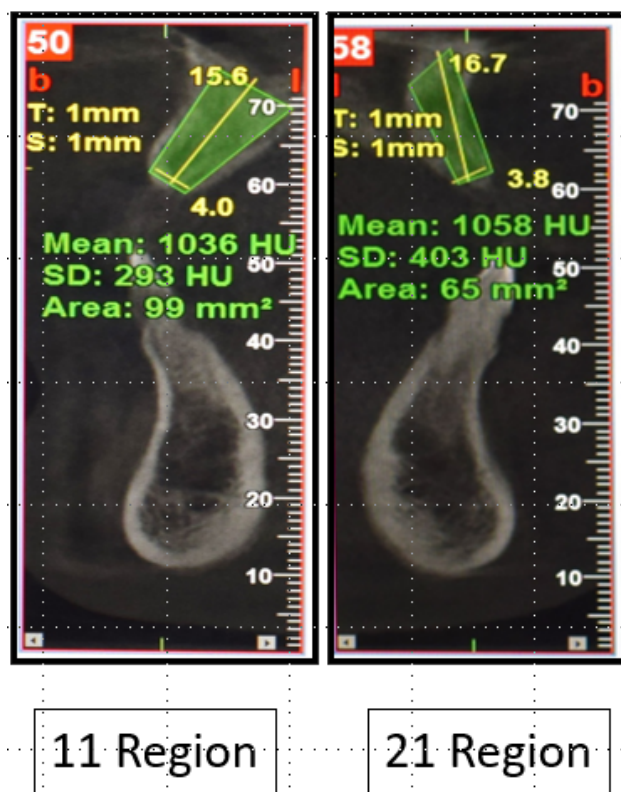


Fig. 2:

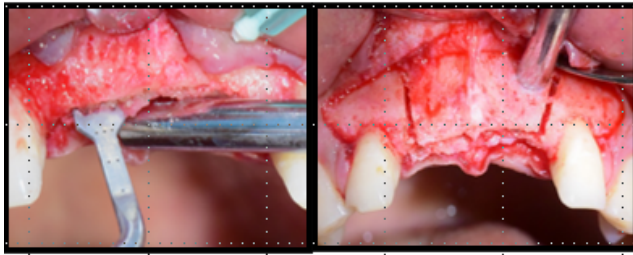


Fig. 3:

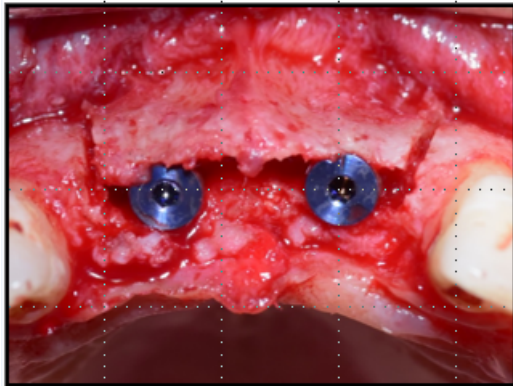


Fig. 4:

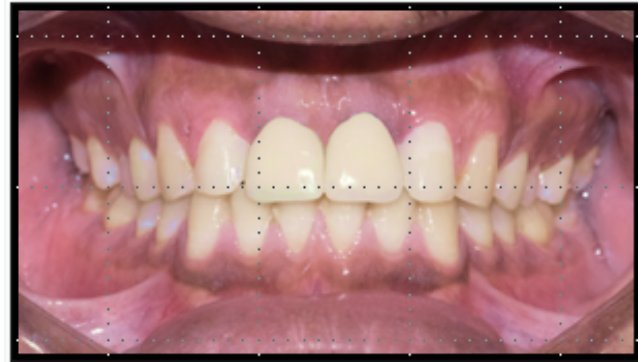


Fig. 6:

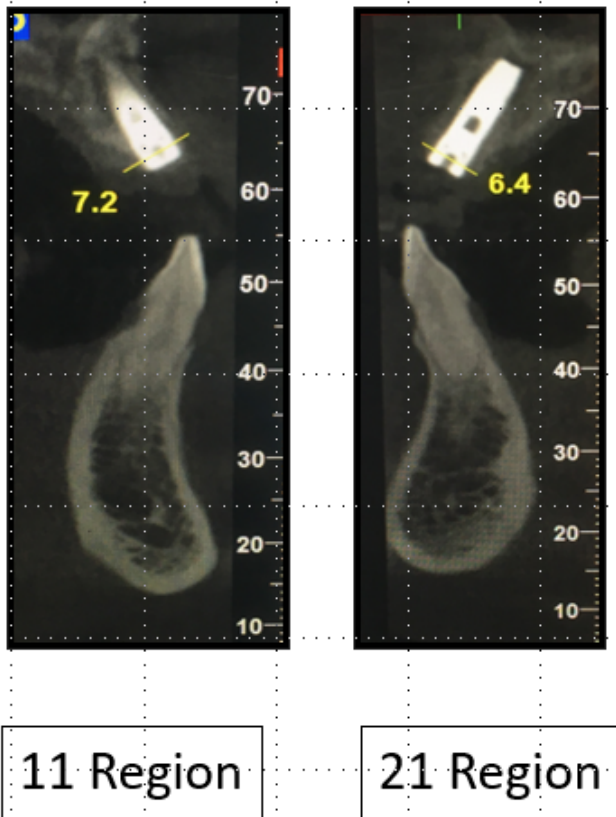


Fig. 5:

### 3. Discussion

Following tooth extraction, the horizontal resorption affects the ridge with dissimilar yet certain patterns. There is accelerated bone loss in the labial wall of maxilla termed as centripetal resorption.<sup>9</sup> The other causes of ridge atrophy involve denture induced atrophy, trauma, periodontal disease, congenital alveolar defects and tumor resection. Alveolar ridge width deficiency can be due to either cortical plate or cancellous bone resorption. However, cortical plate deficiency affects the implant survival to a greater degree because subsequently it can cause implant dehiscence after implant insertion and enhanced bone loss following implant loading.<sup>10</sup> A variety of classifications have been proposed to address the horizontal, vertical and combination defects and their treatment needs based on clinical evaluation or radiographic evaluation.<sup>11–14</sup> A clinically relevant implant-driven classification of the alveolar ridge width was proposed by Tolstunov,<sup>15</sup> with the goal to assist an operator in choosing the proper bone augmentation technique. This classification projected eight classes to match the specific ridge topography and width with an appropriate surgical technique that can be used to that particular case of ridge width. Comparing the many techniques that were advocated for implant placement in horizontally deficient ridge, ridge-split provides several advantages such as predictable ridge expansion of 2–4 mm, graft stability and decreased postoperative graft exposure, lack of donor site morbidity as with Onlay block grafting and remarkably allows immediate implant insertion.<sup>15</sup> Simion et al. in 1992, first introduced the ridge split technique to provide implant driven treatment for horizontally resorbed ridges.<sup>16</sup> Following that several modifications to original technique have been proposed. Minimum ridge width required for ridge split is 3–4 mm and an adequate ridge height of >10 mm is required to achieve primary stability during immediate implant placement.<sup>17</sup> In this case, the patient had an initial ridge width of <4 mm, and hence ridge splitting was planned anticipating an increase of 3 mm ridge width. Ridge split creates a 4-wall defect with cortical envelope



and simulates an extraction socket.<sup>15</sup> An internal coagulum that forms with the placement of interpositional grafting helps in healing and woven bone formation. This technique provides excellent protection to the graft from exposure and displacement, also delivers vascularization from both the cortices and basal bone by internal perfusion throughout the whole healing process.

In a study conducted by Yoon et al., the implant survival rate after ridge-split procedure during an average follow-up period of  $4.2 \pm 2.1$  years was 100% regardless of the implant system and complications.<sup>18</sup> Thus, in the present case, the crestal ridge split technique provided a predictable outcome and allowed reduced treatment duration by cutting off the waiting time for the second surgery. However, the limitation of the technique used, is a risk of buccal bone fracture when excessive force is delivered which makes the procedure technique sensitive.<sup>19</sup>

#### 4. Conclusion

Implants in anterior maxillary region are considered to be predictable and stable with high success rate and patient's satisfaction with implant esthetics. In contrast to traditional ridge augmentation techniques, ridge split technique allows for immediate implant placement following surgery and eradicates the possible morbidity from a second surgical site. Further long-term follow-up studies of several cases are needed to ensure the predictability of the procedure.

#### 5. Conflicts of Interest

All contributing authors declare no conflicts of interest.

#### 6. Source of Funding

None.

#### References

- Ashman A, Lopinto J, Rosenlicht J. Ridge augmentation for immediate postextraction implants: eight year retrospective study. *Pract Periodontics Aesthet Dent*. 1995;7(2):85–94.
- Tolstunov L. Horizontal Alveolar Ridge Augmentation in Implant Dentistry: A Surgical Manual. John Wiley & Sons; 2015.
- Keller EE, Triplett WW. Iliac bone grafting: a review of 160 consecutive cases. *J Oral Maxillofac Surg*. 1987;45(1):11–4.
- Tolstunov L. Maxillary tuberosity block bone graft: innovative technique and case report. *J Oral Maxillofac Surg*. 2009;67(8):1723–9.
- Annibaldi S, Bignozzi I, Sammartino G. Horizontal and vertical ridge augmentation in localized alveolar deficient sites: a retrospective case series. *Implant Dent*. 2012;21(3):175–85.
- Mccarthy JG. The role of distraction osteogenesis in the reconstruction of the mandible in unilateral craniofacial microsomia. *Clin Plast Surg*. 1994;21(4):625–31.
- Jensen OT, Ringeman JL, Cottam JR. Orthognatic and osteoperiosteal flap augmentation strategies for maxillary dental implant reconstruction. *Oral Maxillofac Surg Clin North Am*. 2011;23(2):301–19. doi:10.1016/j.coms.2011.01.004.
- Kheur M, Gokhale SG. Orthognatic and osteoperiosteal flap augmentation strategies for maxillary dental implant reconstruction. *J Oral Implantology*. 2011;4:479–83.
- Qahash M, Susin C, Polimeni G, Hall J, Wikesjö UM. Bone healing dynamics at buccal peri-implant sites. *Clin Oral Implants Res*. 2008;19(2):166–72.
- Cawood JI, Howell RA. A classification of the edentulous jaws. *Int J Oral Maxillofac Surg*. 1988;17(4):232–6.
- Jensen O. Site classification for the osseointegrated implant. *J Prosthet Dent*. 1989;61(2):228–34. doi:10.1016/0022-3913(89)90380-6.
- Wang HL, Al-Shammari K. HVC ridge deficiency classification: A therapeutically oriented classification. *Int J Periodontics Restorative Dent*. 2002;22(4):335–43.
- Guideline: Cologne Classification of Alveolar Ridge Defects (CCARD). In: Consensus Paper Approved at the 8th European Consensus Conference (EuCC) in Cologne; 2013.
- Simion M, Baldoni M, Zaffe D. Jawbone enlargement using immediate implant placement associated with a split-crest technique and guided tissue regeneration. *Int J Periodontics Restor Dent*. 1992;12(6):462–73.
- Tolstunov L. Classification of the alveolar ridge width: Implant-driven treatment considerations for the horizontally deficient alveolar ridges. *J Oral Implantol*. 2014;40:365–70. doi:10.1563/aaid-joi-D-14-00023.
- Tolstunov L, Hicke B. Horizontal augmentation through the ridge-split procedure: A predictable surgical modality in implant reconstruction. *J Oral Implantol*. 2013;39(1):59–68. doi:10.1563/AAID-JOI-D-12-00112.
- Shivashankar VY, Johns DA, Vidyanath S, Sam G. Combination of platelet rich fibrin, hydroxyapatite and PRF membrane in the management of large inflammatory periapical lesion. *J Conserv Dent*. 2013;16(3):261–4.
- Yoon JM, Kim YT, Jang YJ, Park JC, Choi SH, Cho KS, et al. The long-term clinical stability of implants placed with ridge splitting technique. *J Korean Acad Implant Dent*. 2011;30:1–8.
- González-García R, Monje F, Moreno C. Alveolar split osteotomy for the treatment of the severe narrow ridge maxillary atrophy: A modified technique. *Int J Oral Maxillofac Surg*. 2011;40:57–64.

#### Author biography

**Abir Sarkar**, Graded Specialist

**Pramod K Chahar**, Graded Specialist

**Vaibhav Jain**, Graded Specialist  <https://orcid.org/0000-0003-0374-8383>

**Vishvnathe Udayshankar**, Graded Specialist

**Cite this article:** Sarkar A, Chahar PK, Jain V, Udayshankar V. Horizontal maxillary ridge augmentation with ridge split procedure and simultaneous implant placement: A case report. *J Dent Spec* 2021;9(1):32-35.