



## Case Report

# Mucormycosis revisited: Case report with review of literature

Arushi Pandey<sup>1</sup>, Gurkiran Kaur<sup>2,\*</sup>

<sup>1</sup>Kshetrapal Orthodontic and Dental Centre, Kota, Rajasthan, India

<sup>2</sup>Dept. of Oral Pathology, PDM Dental College & Research Institute, Bahadurgarh, Haryana, India



### ARTICLE INFO

#### Article history:

Received 07-07-2020

Accepted 10-09-2020

Available online 23-11-2020

#### Keywords:

Amphotericin B

Fungi

Mucormycosis

### ABSTRACT

Invasive fungal infections caused by the members of Mucoromycotina (mucormycosis) are relatively rare but have increased in the last years. These aggressive and highly destructive infections fail to induce disease in most immunocompetent persons but can do so in those with impaired host defenses. Compared to other fungal pathogens, such as *Aspergillus fumigatus* or *Candida albicans*, only little is known so far on the fungal properties leading to successful infection and host immune response to the various representatives of the Mucorales. This article explains the new nomenclature, clinical manifestations, risk factors and focuses on virulence traits associated with mucormycosis. Early diagnosis and prompt treatment can reduce the mortality and morbidity of this lethal fungal infection.

© This is an open access article distributed under the terms of the Creative Commons Attribution License (<https://creativecommons.org/licenses/by/4.0/>) which permits unrestricted use, distribution, and reproduction in any medium, provided the original author and source are credited.

## 1. Introduction

Mucormycosis is a rare opportunistic fulminant fungal infection caused by saprophytic fungi.<sup>1</sup> According to Brown, mucormycosis ranked third among opportunistic deep fungal infections, after Candidiasis and Aspergillosis.<sup>2</sup> It is frequently found in soil, residue plants, spoiled food and upper respiratory tract of healthy individuals.<sup>3</sup> It becomes pathogenic when associated with predisposing factors such as immunocompromised states, most commonly (60–81%) diabetes mellitus.<sup>4,5</sup> The other predisposing factors are malignancies like lymphomas and leukemia's, renal failure, organ transplant, long term immunosuppressant therapy, cirrhosis, burns, protein energy malnutrition and acquired immunodeficiency syndrome. It can manifest as any one of the different clinical forms such as Rhino Orbitocerebral, Pulmonary, Gastrointestinal, Central nervous system, Cutaneous and Miscellaneous (bones, joints, heart, kidney, mediating).<sup>6</sup>

Early diagnosis, and prompt treatment can reduce the mortality and morbidity of this lethal infection. Therefore,

this article with the help of a case report encompasses complete review on the nomenclature, risk factors, virulent traits, early diagnostic methods and treatment modalities associated with mucormycosis.

## 2. Case Report

A 60-year-old female reported to the dental clinic, with the complaint of severe pain in right upper jaw since past 2 months. She reported of an assault 2 months ago, with impact forced directly over the right temporal region. The patient had severe continuous pain extending from the temple region superiorly to the level of the corner of the mouth inferiorly, and from the midline to the external ear posteriorly, which showed reduction in intensity to taking analgesics. Extractions were done for 16, 17, 18 teeth at a private clinical setup.

On intraoral examination, the mucosa overlying right palatal and alveolar process of maxilla was showing bluish discoloration and hard non-pitting tender swelling with white pus discharge from multiple sinus openings overlying the buccal cortical plate adjacent to 12, 13, 14, 15 teeth region. Greyish-white denuded necrotic bone was present in

\* Corresponding author.

E-mail address: [gurkirankaur@yahoo.com](mailto:gurkirankaur@yahoo.com) (G. Kaur).

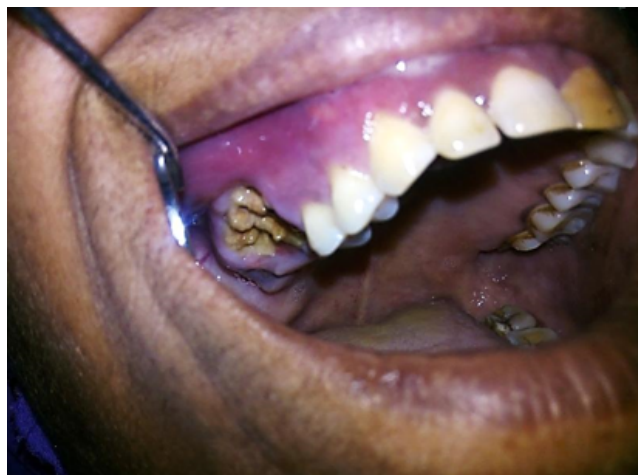the unhealed extraction sockets of 16, 17, and 18, covered with scrapable grey slough. All the teeth in the first quadrant were grade II mobile, showing tenderness on percussion and palpation; with mobility extending to the whole of the maxillary alveolar and palatal processes, though no occlusal discrepancy was observed. (Figure 1)

There was moderate nasal congestion, with continuous discharge of small amounts of white mucous from the nose, with no history of fever, chills or bleeding, vision impairment or facial paraesthesia.

Routine blood investigations were carried out to rule out HIV, Hepatitis-B and diabetes mellitus. Random blood sugar levels were found to be as high as 461 mg/dl indicating uncontrolled diabetic status; hence, the patient was referred to a general physician for diabetes control, who started with Human MIXTARD- 20 IU in the morning and 10 IU in the evening. The OPG view revealed fracture at the junction of the alveolar process and the zygomatic process of right maxilla with hazy radio opacity in the right maxillary sinus, and unhealed sockets in the right maxilla, posterior to 15 region (Figure 2).

The CT scan in the sagittal and coronal planes showed involvement of right maxillary sinus with isodensity extending up to the middle and inferior conchae of the right lateral nasal wall. (Figure 3)

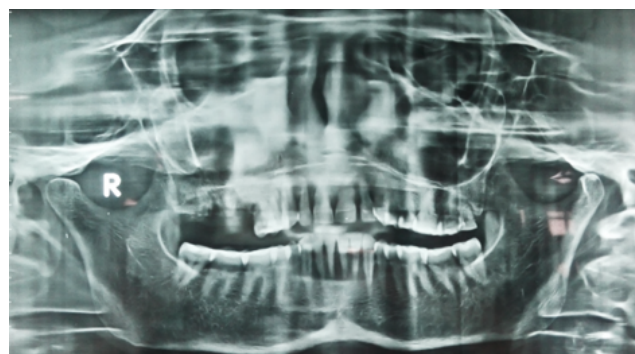
A bone biopsy was performed and the histopathologic report revealed showing branching aseptate PAS positive mycelia suggestive of Mucormycosis of the right maxilla (Photomicrographs Figures 4, 5 and 6).



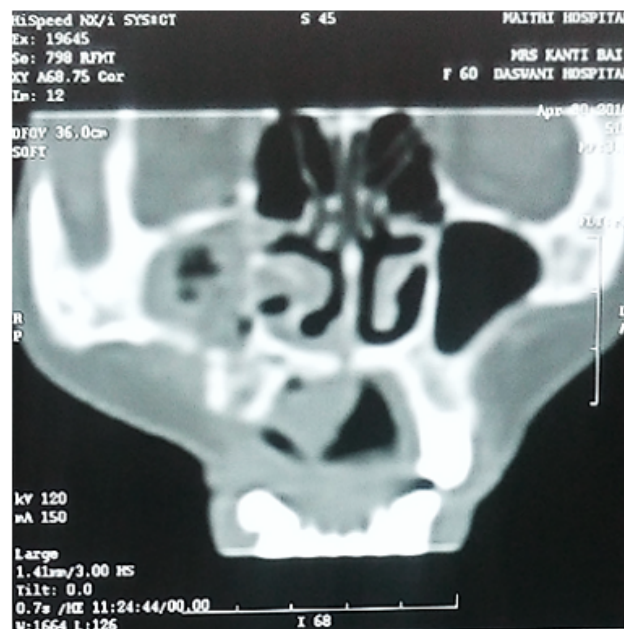**Fig. 1:** Clinical examination showing lesion covered with grayish white slough

### 3. Discussion

Fungi are eukaryotic organisms which may exist in two forms -yeast and molds. Yeast grow as single cells that reproduce asexually. Molds grow as long filaments (hyphae) and form a mat (mycelium). Some form transverse walls



**Fig. 2:** OPG showing maxillary involvement in the right side alveolar bone and maxillary sinus

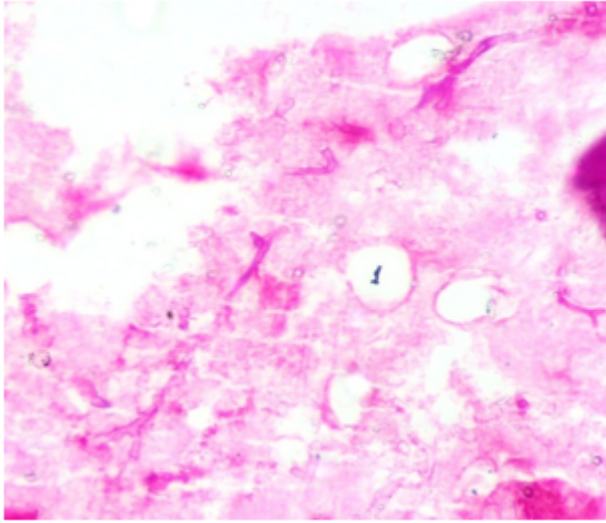


**Fig. 3:** CT scan showing bone involvement up to lateral nasal wall

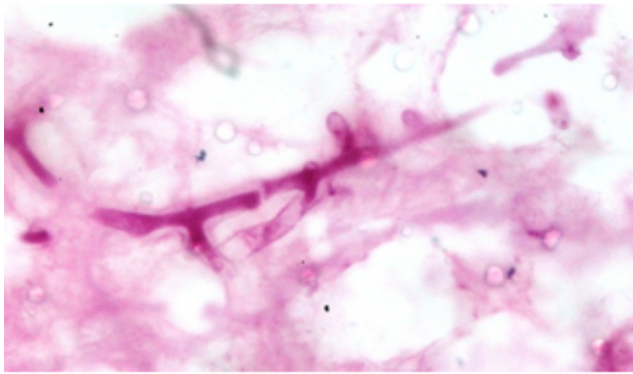
(septate) as in *Aspergillus*, whereas others do not (non septate) as in *Mucor*. Most fungi are obligate aerobes, some facultative anaerobes but non obligate anaerobes. All fungi require a preformed source of carbon- hence their frequent association with decaying matter. The natural habitat of most fungi is therefore the environment. An important exception is *Candida albicans* which is part of the human oral flora.<sup>7</sup>

#### 3.1. Nomenclature

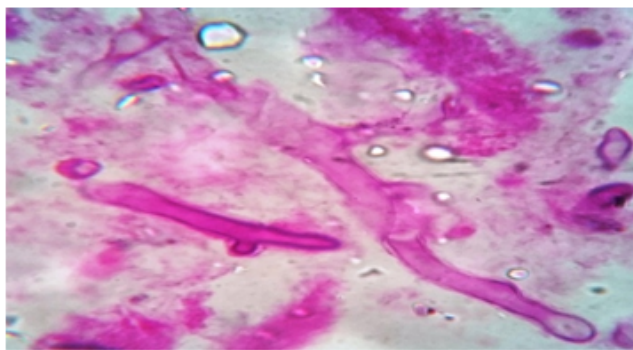
Until more than a decade ago, the phylum Zygomycota comprised of the Mucorales, Entomophthorales and eight other orders.<sup>8</sup> A comprehensive phylogenetic reanalysis of kingdom Fungi, based on molecular methods, resulted in elimination of the polyphyletic phylum Zygomycota and placing the various taxa into



**Fig. 4:** Photomicrograph: Low power view of mycelia in PAS stain 10x



**Fig. 5:** Photomicrograph: High power view of PAS positive stained mycelia 40x



**Fig. 6:** Photomicrograph : 100x view showing aseptate PAS positive mycelia

the phylum Glomeromycota divided into four subphyla: Mucoromycotina, Entomophthoromycotina, Kickxellales and Zoopagomycotina (elevating the orders Mucorales and Entomophthorales to subphylum status).<sup>9-11</sup>

The changes in taxonomy were accompanied by a renaming of the disease caused by these aetiologic agents. The term "zygomycosis", defined by Ajello et al.,<sup>12</sup> and describing any invasive fungal infection caused by species of the former phylum Zygomycota was replaced by either "mucormycosis" or "entomophthoromycosis".<sup>13</sup>

### 3.2. General characteristics

Mucoromycotina are saprophytic moulds found widely in the environment on decaying organic material or agricultural and forest soils. They are not dimorphic. They are fast growing organisms, characterized by large, ribbon-like, and irregularly shaped, nonseptate (coenocytic), or sparsely septate, with branches often arising nondichotomously at right angles. The genera mainly involved in human disease are Cunninghamella, Lichtheimia (formerly Absidia), Mucor, Rhizomucor, Rhizopus, Apophysomyces and Saksenaea.<sup>14,15</sup>

### 3.3. Virulence traits

Mucoromycotina are thermotolerant and therefore able to grow at 37°C, some at even higher temperatures. Nevertheless, according to Schwartze et al.,<sup>16</sup> no clear correlation between growth speed at host temperature and differences in virulence potential was detected. The second, virulence factor is iron acquisition, as iron is an essential element for fungal cell growth and development. Three general mechanisms of iron uptake have been identified in fungi. These include a reductive iron uptake, a siderophore-permease that facilitates the uptake of siderophore-sequestered iron and an uptake system for acquiring iron from haem.<sup>17</sup> Recently, another factor, the glucose regulated protein 78 (GRP78) has been identified to enable invasion of the pathogen through endocytotic mechanism. Another aspect contributing to virulence of a pathogen is its capability to evade recognition and elimination by the host immune system.<sup>18</sup>

### 3.4. Risk groups

Highest at risk for the development of mucormycosis are those patients who either have decreased amounts of mononuclear and polymorphonuclear phagocytes, that would inhibit germination of spores in healthy humans, or whose underlying disease disturbs the function of their phagocytic cells such as those with haematological malignancies.<sup>19</sup> In diabetic ketoacidosis patients, elevated levels of free iron in serum are caused by a release of iron from binding proteins such as transferrin, which is due to a decreased pH level. The dysfunction of glucose and iron

metabolism, and regulation of this, was shown to result in decreased phagocytic function and intracellular killing of *R. oryzae*.<sup>20</sup>

### 3.5. Pathogenesis

These organisms are transmitted by air borne asexual spores and invade tissue of patients with reduced host defenses via respiratory tract, injured skin or via percutaneous route. Fungal hyphae have high affinity to the internal elastic lamina of arterial blood vessels and are extremely angioinvasive ensuing thromboembolism and cause subsequent thrombotic infarction. They proliferate in the walls of blood vessels particularly paranasal sinuses, lungs or gut and cause infarction and necrosis of the tissue distal to the blocked vessels.<sup>21,22</sup> Increased levels of free iron present in diabetic patients assist the growth of these organisms.<sup>17</sup>

### 3.6. Clinical features

Rhino-orbital-cerebral form of mucormycosis defines an infection that originates in the paranasal sinuses, following inspiration of spores and possible extension to the brain. Sequentially nose, sinuses, eyes and brain are affected. Symptoms at early stage of disease might be sinus pain, nasal congestion, fever, soft tissue swelling and headache. Nasal ulceration might occur. Progression of disease is usually rapid if not treated and results in extension to neighboring tissues, thrombosis and further necrosis causing painful dirty brown-black eschar on the maxilla or nasal mucosa. Extension to the eyes is possible leading to blurred vision or complete blindness. From the eyes the disease can progress towards the central nervous system resulting in altered consciousness, cranial neuropathies or cerebral abscesses.<sup>23</sup>

### 3.7. Identification

Early diagnosis of mucormycosis is critical to enable early initiation of active antifungal therapy. The symptoms, signs and radiographic manifestations of mucormycosis are nonspecific and a definitive diagnosis requires direct identification of the characteristic hyphae or the recovery of organism in culture from specimens obtained from the site of infection.

**Cytopathology:** The hyphae may be difficult to observe on an unenhanced Potassium hydroxide wet mount and may not stain well with conventional Gram stain. The use of chitin binding stains, such as Calcoflour, Fungi-flour, or Blanford flour, may be used with a fluorescent microscope to identify hyphal elements on Potassium hydroxide wet mounts.<sup>24</sup>

**Histopathology:** The histological detection of mucorales organisms in tissue and their interpretation may be difficult. These organisms are typically difficult to observe on

hematoxylin-eosin stains. On the other hand, Periodic acid Schiff and Gomori methenamine silver stains may be used for a fully characterized appearance of the organism. Microscopic characterization of nonseptate hyphae, rhizoids, columellae, sporangia and sporangiospores help to define genus and species within the order mucorales.<sup>24</sup>

**Culture:** To optimize growth, clinical specimens should be inoculated onto appropriate media, such as Sabouraud's dextrose agar, and incubated at room temperature and 37°C. Grinding or homogenization of tissue specimens may destroy the delicate hyphae, rendering culture results negative. Recovery in culture is enhanced if tissue is sliced or minced into small pieces before inoculation onto media. Close collaboration between clinicians and the microbiology laboratory is essential to ensure proper handling of the specimen. Although mucorales species are angioinvasive, blood culture results are rarely positive, unless there is luminal involvement of a vascular catheter. Colonies typically appear within 24-48 hours unless residual antifungal agents such as Amphotericin B are present which can suppress growth. The colonial appearance and growth pattern in culture help distinguish mucorales. Most mucoraceous species fill a culture disc in 3-5 days and demonstrate a grayish white, aerial mycelium with a wooly texture. The colonies readily separate from the agar surface.<sup>25</sup>

**Radiography/ Imaging Techniques:** Pre operative contrast-enhanced computed tomography (CT) is useful in defining the extent of the disease. Scan show the edematous mucosa, fluid filling the sinuses and destruction of the peri-orbital tissue and bony margins, although sinus CT is the preferred imaging modality, bony destruction is often seen only late in the course of the disease. Magnetic Resonance Imaging (MRI) is useful in identifying the intradural and intracranial extent of the disease, cavernous sinus thrombosis, or thrombosis of the cavernous portion of the internal carotid artery. Perineural spread of the disease can also be demonstrated with contrast enhanced MRI scan.<sup>26</sup>

### 3.8. Other modalities

Thorough medical history, biochemical tests, and molecular analysis like Polymerase Chain Reaction systems enable rapid diagnosis.<sup>24</sup>

#### 3.8.1. Treatment modalities

It is critical to reverse /prevent underlying defects in host defense when treating patients with mucormycosis. Immunosuppressive medications, particularly corticosteroids, should be dose reduced or stopped if at all possible. Aggressive management to rapidly restore euglycemia and normal acid base status is critical in diabetic patients in ketoacidosis. Administration of iron should be avoided, because it exacerbates the severity of

infection in animal models.

Blood vessel thrombosis and resulting tissue necrosis during mucormycosis can result in poor penetration of antifungal agents to the site of infection. Therefore debridement of necrotic tissues may be critical for complete eradication of mucormycosis.<sup>27</sup>

Aggressive medical treatment with conventional antifungals and non-conventional therapeutics are corner stone for successful treatment.<sup>28</sup> Polyenes like Amphotericin-deoxycholates and lipid complex are primary therapeutic agents for mucormycosis. The dosage varies from 0.5-1.0mg/kg body weight once daily for not less than 4 weeks. There should be close monitoring of serum electrolytes, as polyenes are known to cause potassium imbalance.<sup>29,30</sup> Salvage therapy by Posaconazole or deferasirox are reasonable options for patients refractory to or intolerant to polyene therapy.<sup>31</sup> Non-conventional therapeutic agents like anti diabetics, iron chelating agents, statins, granulocyte transfusions, cytokines, and hyperbaric oxygen have increased the survival rates to 94%. Prevention always remains a gold standard.<sup>28</sup>

#### 4. Conclusion

Mucormycosis is an aggressive fungal infection. It is an essential task for clinicians to pick these infections at early stage. Histopathological studies are of great help in determining the diagnosis. Oral surgeons play an important role as oral manifestations are first to appear, especially in severely immunocompromised patients. Thus, successful treatment of mucormycosis requires four steps 1) early diagnosis; 2) reversal of underlying predisposing risk factors, if possible; 3) surgical debridement where ever applicable; and 4) prompt antifungal therapy.

#### 5. Source of Funding

None.

#### 6. Conflict of Interest

None.

#### References

1. Farmakiotis D, Kontoyiannis DP. Mucormycoses. *Infect Dis Clin North Am.* 2016;30(1):143–63.
2. Brown J. Zygomycosis: an emerging fungal infection. *Am J Health Syst Pharm.* 2005;62(24):2593–6.
3. Koe Z, Koe F, Yerdelin D, Dogu O, H. Rhino-Orbital-Cerebral Mucormycosis with Different Involvement. Infarct, hemorrhage and ophthalmoplegia. *Int J Neurosci.* 2007;117(12):1677–90.
4. Bhansali A, Bhadada S, Sharma A, Suresh VP, Gupta A, Singh P, et al. Presentation And Outcome Of Rhino-Orbital-Cerebral Mucormycosis In Patients With Diabetes. *Post Grad Med J.* 2004;80(949):670–4.
5. Cohen SG, Greenberg MS. Rhinomaxillary mucormycosis in a kidney transplant patient. *Oral Surg, Oral Med, Oral Pathol.* 1980;50(1):33–38.
6. Rickerts V, Just-Nübling G, Konrad F, Kern J, Lambrecht E, Böhme A, et al. Diagnosis of invasive aspergillosis and mucormycosis in immunocompromised patients by seminested PCR assay of tissue samples. *Eur J Clin Microbiol Infect Dis.* 2006;25(1):8–13.
7. Levinson W, Jawetz E. Medical Microbiology & Immunology. 6th ed. Lange Medical Books; 2000.
8. Kirk PM, Cannon PF, David JC, Staplers JA. Ainsworth and Bisby's Dictionary of Fungi. 9th ed. Wallingford, UK: CAB International; 2001.
9. James TY, Kauff F, Schoch CL, Matheny PB, Hofstetter V, Cox CJ. Reconstructing The Early Evolution Of Fungi Using A Six Gene Phylogene. *Nature.* 2006;443(7113):818–22.
10. Keeling PJ. Congruent Evidence From Alpha-Tubulin And Beta Tubulin Gene Phylogenies For A Zygomycete Origin Of Microsporidia. *Fungal Genet Biol.* 2003;38(3):298–309.
11. Hammond SP, Badu LR, Marty FM. Mortality In Hematologic Malignancy And Hemopoietic Stem Cell Transplant Patients With Mucormycosis. *Antimicrob Agents Chemother.* 2001;55(11):5018–21.
12. Chung KJK. Taxonomy Of Fungi causing Mucormycosis And Entomophthoromycosis (Zygomycosis) And Nomenclature Of Disease; Molecular Mycologic Perspective. *Clin Infect Dis.* 2012;54(1):S8–15.
13. Kontoyiannes DP, Lionakis MS, Lewis RE, Chamilos G, Healy M, Peregó C, et al. Zygomycosis In A Tertiary-Cancer Center in Era Of Aspergillosis-Active Fungal Therapy: A Case Control Observational Study Of 27 Recent Cases. *J Infect Dis.* 2005;191(8):1350–60.
14. Chung KJK, Varma A, Edman JC, Bennett JE. Selection of *ura5* and *ura3* mutants from the two varieties of *Cryptococcus neoformans* 5-fluoroorotic acid medium. *Medical Mycology.* 1992;30(1):61–9.
15. Hoog GSD, Guarro J, Figuera GJ, J M. Atlas of clinical fungi. 2nd ed. Utrecht, Netherlands: Centraalbureau voor Schimmelcultures (CBS); 2011.
16. Schwartze VU, Hoffmann K, Nyilasi I, Papp T, Vágvölgyi C, d Hoog S, et al. Lichtheimia Species Exhibit Differences in Virulence Potential. *PLoS One.* 2012;7(7):e40908.
17. Ibrahim AS, Spellberg B, Edwards J. Iron acquisition: a novel perspective on mucormycosis pathogenesis and treatment. *Curr Opin Infect Dis.* 2008;21(6):620–5.
18. Binder U, Maurer E, Flörl CL. Mucormycosis – from the pathogens to the disease. *Clin Microbiol Infect.* 2014;20(6):60–6.
19. Ibrahim AS. Host cell invasion in mucormycosis: role of Iron. *Curr Opin Microbiol.* 2011;14(6):406–11.
20. Teixeira CA, Medeiros PB, Leushner P, Almeida F. Rhinocerebral mucormycosis: literature review apropos of a rare entity. *BMJ Case Rep.* 2013;.
21. Bitar D, Cauteren DV, Lanternier F, Danaoui E, Cha D, Dromer F, et al. Increasing incidence of zygomycosis (Mucormycosis). *Emerg Infect Dis.* 1997;15(9):1395–401.
22. Sun HY, Singh N. Mucormycosis: Its Contemporary Phase and Management Strategies. *Lancet Infect Dis.* 2011;11(4):301–11.
23. Walsh TJ, Gamaletsou MN, McGinnis MR, Hayden RT, Kontoyiannis DP. Early Clinical and Laboratory Diagnosis of Invasive Pulmonary, Extrapulmonary, and Disseminated Mucormycosis (Zygomycosis). *Clin Infect Dis.* 2012;54(1):S55–60.
24. Ibrahim AS, Spellberg B, Walsh TJ, Kontoyiannis DP. *Cin Infect Dis.* 2012;54(1):S16–22.
25. Franquet T, Giménez A, Hidalgo A. Imaging of opportunistic fungal infections in immunocompromised patient. *European Journal of Radiology.* 2004;51(2):130–8.
26. Spellberg B, Ibrahim AS. Recent advances in the treatment of mucormycosis. *Curr Infect Dis Rep.* 2010;12(6):423–9.
27. Shetty SR, Puniya VA. Palatal mucormycosis: A rare clinical dilemma. *Oral Surg.* 2008;1:145–8.
28. Aggarwal P, Saxena S, Bansal V. Mucormycosis of maxillary sinus. *J Oral Maxillo Path.* 2012;11(2):66–9.
29. Prasad K, Lalitha RM, Reddy EK, Ranganath K, Srinivas DR, Singh J. Role of Early Diagnosis and Multimodal Treatment in Rhinocerebral Mucormycosis: Experience of 4 Cases. *J Oral Maxillofac Surg.* 2012;70(2):354–62.
30. van Burik JAH, Hare RS, Solomon HF, Corrado ML, Kontoyiannis DP. Posaconazole Is Effective as Salvage Therapy in Zygomycosis: A

Retrospective Summary of 91 Cases. *Clin Infect Dis.* 2006;42(7):e61-5.

31. Greenberg RN, Mullane K, Burik JAV, Raad I, Abzug MJ, Anstead G, et al. Posaconazole As A Salvage Therapy For Zygomycosis. *Antimicrob Agents Chemother.* 2006;50(1):126-33.

**Gurkiran Kaur**, Professor and HOD

**Cite this article:** Pandey A, Kaur G. Mucormycosis revisited: Case report with review of literature. *J Dent Spec* 2020;8(1):39-44.

### **Author biography**

**Arushi Pandey**, Consultant Oral Pathologist