

Conservative management of oral pyogenic granuloma with diode laser: A case report

Preeti Sharma^{1*}, Prerna Mohan², Shubhra Vaish³, Nikhil Sharma⁴

^{1,2}PG Student, ³Professor, ⁴HOD, ^{3,4}Dept. of Periodontology and Implantology, ¹⁻⁵I.T.S-CDSR Muradnagar, Ghaziabad, Uttar Pradesh, India

***Corresponding Author: Preeti Sharma**

Email: drpreetimds@gmail.com

Abstract

The oral pyogenic granuloma is a commonly occurring tumor like reactive lesion that occurs as a response to different stimuli such as hormonal imbalances, low grade chronic irritation, trauma or certain type of drugs and oral contraceptives. It is frequently seen in the gingiva, and also lips, tongue and buccal mucosa are the other commonest sites. The present case reports a localized inflammatory hyperplasia of the maxillary gingiva of a 20-year-old male patient which was interfering with normal eating and brushing.

Keywords: Pyogenic granuloma, Diode laser, Gingival enlargement.

Introduction

Pyogenic granuloma (PG) is a well-known benign inflammatory hyperplastic growth seen inside the oral cavity as a tissue reaction to irritation, trauma, or hormonal imbalances. The term “pyogenic granuloma” is misnomer as it is a non-neoplastic lesion of vascular origin, also it does not contain pus nor it is granulomatous. It is considered as capillary haemangioma. It was first described by Hullihen in 1844.¹ Other names for the pyogenic granuloma are granulation tissue-type haemangioma, granuloma gravidarum, lobular capillary haemangioma, pregnancy tumour, eruptive haemangioma.²

It is presented as an elevated sessile or pedunculated growth, surfaced with red hemorrhagic and erythematous papules covered by a fibrinous membrane that usually shows ulcerations. Based on the vascularity of the lesion, the color varies from purple pink to red. Clinically, the lesion rarely exhibits rapid growth, is symptomless, and does not cause pain. The radiographic findings are typically absent, but in long standing gingival Pyogenic granuloma, localized alveolar bone resorption can be seen.³ Marginal gingiva is the most common intraoral site to be affected by pyogenic granuloma but lesions have been reported on palate, buccal mucosa, tongue, and lips. The skin of face, neck, upper and lower extremities, and mucous membrane of nose and eyelids are also commonly involved extraoral sites.²

The Conventional Excisional therapy is the treatment of choice for pyogenic granuloma, but some alternative approaches such as cryosurgery, electrosurgery, laser therapy, flash lamp pulsed dye laser, injection of corticosteroid or ethanol, sclerotherapy have been reported to be effective. The definitive treatment involves excision of the lesion along with histopathological evaluation to confirm the diagnosis. Careful monitoring is necessary during the excision of PG because of its vascular nature leading to profuse bleeding and it should be completely removed otherwise recurrence chance is more. The biggest disadvantage of conventional surgical excision is difficulty of controlling bleeding during the surgical procedure.^{4,5}

Since the introduction of laser in dentistry, different wavelengths have been used for oral soft tissue dental procedures. Various laser devices have been successfully used to treat PG, such as neodymium-doped yttrium aluminium garnet (Nd:YAG), carbon dioxide laser, erbium-doped yttrium aluminum garnet (Er:YAG), and the diode laser. The dental laser is able to provide clean incision of tissues, immediate coagulation, and minimal postoperative pain, and edema. Minimum surgical expertise is required with laser therapy as compared to conventional surgical excision.^{6,7}

The diode laser acts as a semiconductor device consisting of several active medium like aluminum, gallium, arsenide, and occasionally indium. The coherent radiation is produced by the device in the visible or infrared spectrum with wavelengths ranging from 810 nm to 980 nm. Thus, the pigmented tissues like melanin and hemoglobin tend to absorb all wavelengths properly. However, they are poorly absorbed by calcified tissue such as hydroxyapatite and water present in the enamel.⁶ Several studies have reported success using diode lasers in surgical procedures performed on soft tissues. Diode laser therapy is simple, safe, non-invasive and completely effective for oral soft tissues. High precision, negligible blood loss and better patient compliance are the advantages associated with it. The diode laser ensures various procedures like Cuts, vaporization, curettage, coagulation, and hemostasis.⁸

This case report presents a case of a peculiar Oral Pyogenic Granuloma in a young adult patient excised successfully with minimal postoperative complications and also highlights the use and advantages of diode laser in the surgical excision of oral pyogenic granuloma.

Case Report

A 20-year-old male patient reported to the outpatient Department of Periodontics with the chief complaint of painless overgrowth of gum related to upper left back teeth region in the oral cavity. The growth was associated with frequent bleeding and interfered with normal eating and brushing. He first noticed the growth 2 months back when it was very small and gradually increased to reach the current

size. (Fig. 1) The medical and family history were not significant. No extraoral swelling was found on extraoral examination. On intraoral examination, during inspection, an elongated oval-shaped, pedunculated mass-like growth seen in relation to the buccal aspect of gingiva with respect to 25, 26 teeth region, measuring approximately 2.5×3 cm. The Colour of the growth was dark red and surface was smooth. The growth covered approximately whole of the interdental region of the teeth. This erythematous and distinct growth was originating from the marginal gingiva and interdental gingiva in relation to 25 and 26. On palpation, the mass was well defined, smooth, and soft to firm in consistency and non-tender. The lesion was bleeding on probing. Periodontal examination revealed 5mm of pocket probing depth in relation to the interdental area between 25 and 26. (Fig. 2) Radiographic examination showed the mild alveolar bone loss in the involved region and hematological examination revealed normal blood values.

The treatment plan included oral prophylaxis and excisional biopsy of the growth with diode Laser. Written informed consent was obtained from the patient prior to the laser excision of the lesion and all necessary precautions were taken throughout the procedure.

The surgical area was anesthetized using local anesthetic agents (2% lidocaine with 1/100,000 epinephrine), the lesion was treated by Soft-tissue Diode Laser (Biolase Epic 10 Diode laser 940nm, USA) with continuous wave, in contact mode with a power output of 2 watt. A 0.4-mm diameter disposable laser fiber optic tip was initiated. (Fig. 3) The tip was moved around the base of the lesion with a circular motion at a slight angle of 5 to 10 degrees. The base of the lesion was cut precisely. As massive hemorrhage from the surgery area was seen, therefore, the laser fiber tip was moved in a sweeping motion on the surgical site in order to achieve coagulation and after 30 seconds the bleeding was stopped. The area was left for healing with secondary intention. (Fig. 4) The procedure took 3-4 minutes to complete. The mass was excised completely as one piece, and immersed in 10% formalin solution and sent for histopathological examination. (Fig. 5) The patient was discharged with well written prescription and all the necessary post-operative instructions for maintenance of good oral hygiene with 0.12% chlorhexidine mouth rinse for 10 days, and scheduled for routine scaling and curettage. He was recalled for followed up to evaluate the healing process. The use of diode laser enabled an optimum combination of clean cutting of the tissue and hemostasis. The patient was extremely comfortable, reported no post-operative complications, and complete healing was observed within 7 days after surgery. (Fig. 6)

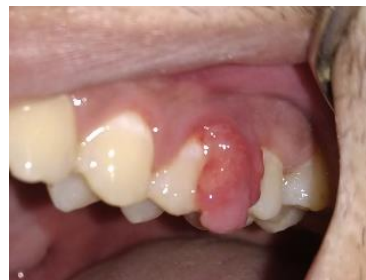

Fig. 1: Preoperative view showing pyogenic granuloma

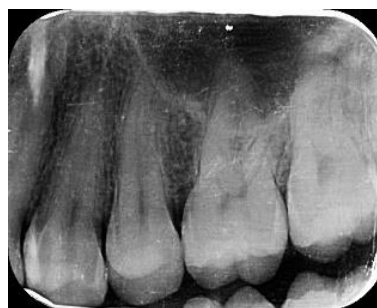

Fig. 2: Preoperative IOPA



Fig. 3: Diode laser

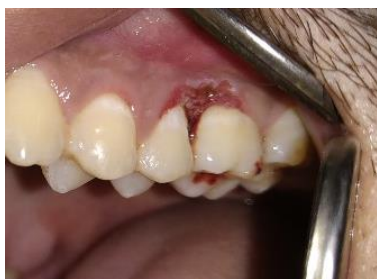

Fig. 4: Diode laser assisted surgical excision of lesion



Fig. 5: Excised tissue sent for histological examination

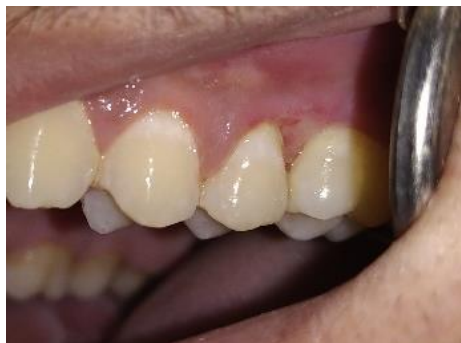

Fig. 6: Post-operative clinical view

Histopathological Examination

The excised mass was sent for histopathologic evaluation. The H&E stained section of tissue showed para keratinized stratified squamous epithelium with thin elongated and irregular rete ridges overlying fibrovascular connective tissue stroma. The epithelium showed prominent nucleoli and prominent intercellular junctions. The underlying fibrovascular connective tissue stroma showed thick and thin collagen fiber bundles interspersed with plump fibroblasts. Numerous blood vessels of varying caliber were seen lined by endothelial cells. Areas of hemorrhage and dystrophic calcifications were also evident. Diffuse mixed inflammatory cell infiltrate was seen chiefly composed of neutrophils, plasma cells and lymphocytes. The above histopathologic features were suggestive of pyogenic granuloma.(Fig. 7-9)

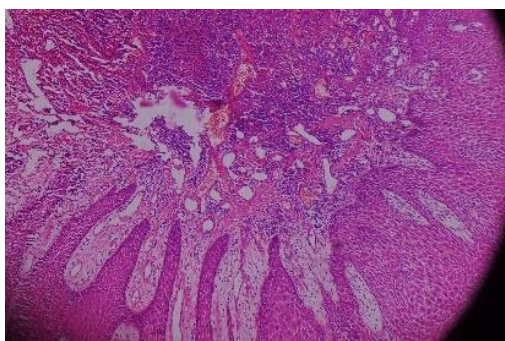


Fig. 7: 10x Histologic section

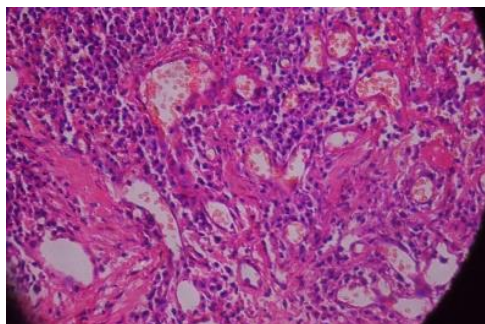


Fig. 8: 20x Histologic section

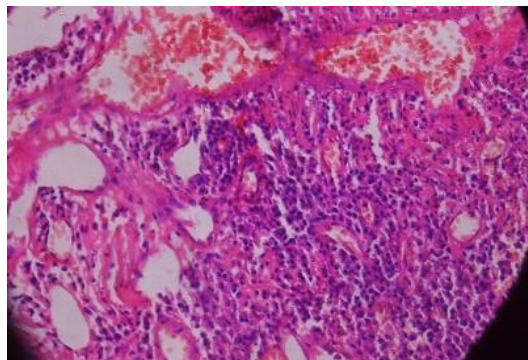


Fig. 9: 30x Histologic section

Discussion

The oral pyogenic granuloma is a most common tumor like reactive lesion having etiological factors such as low grade chronic irritation, hormonal imbalances, trauma or certain type of drugs and oral contraceptives. It occurs at any age but most frequently affecting young adults and women. The anterior maxillary gingiva is involved more frequently than the mandibular gingiva; the facial gingiva is involved more than the lingual gingiva. Poor oral hygiene and chronic oral irritation are most frequent risk factors. Early lesions bleed easily due to extreme vascularity and have a rapid growth pattern.¹⁰

Histopathologically, oral pyogenic granuloma is considered into lobular capillary hemangioma (LCH) because of its inflammatory nature and presence of multitudinal blood vessels. The histologic appearance of pyogenic granuloma shows exuberant granulation tissue which is covered by hyperplastic epithelium that may be ulcerated at times. It is characterized by the presence of numerous endothelium-lined vascular spaces and proliferation of fibroblasts and budding endothelial cells. Presence of mixed inflammatory cell infiltration can also be observed. The differential diagnosis of pyogenic granuloma includes peripheral giant cell granuloma, pregnancy tumor, peripheral ossifying fibroma, bacillary angiomatosis, metastatic cancer, kaposi's sarcoma, and non-hodgkin's lymphoma, angiosarcoma, hyperplastic gingival inflammation and hemangioma.¹¹

Conservative surgical excision of a pyogenic granuloma is the treatment of choice. Depending on the extent and size of the lesion management of pyogenic granuloma varies. The excised tissue should be submitted for histopathologic examination to make a proper diagnosis. Bleeding, suturing, and postoperative discomfort are the major drawbacks of surgical intervention. Re-excision is necessary in case if the lesion recurs. Other less invasive treatment modalities have been attempted in the past with limited benefits, such as: cryosurgery, cauterization with silver nitrate, sclerotherapy.¹²

Among the various treatment modalities, the advantages of laser application are relatively bloodless surgery, better visualization of the site and a sutureless procedure with minimal postoperative pain. Additionally, the laser instantly disinfects the surgical wound with

consequent less postoperative infection, minimal swelling, and enhanced healing. In areas where aesthetics are important, the laser is a less invasive method compared to scalpel and cryosurgery techniques. Laser excision was reported to be well tolerated by patients with no or minimal adverse effects.¹³

Relatively smaller size and lower cost make the diode laser most suitable to use in various surgical indications in comparison with other laser equipment.¹⁴ Iyer and Sasikumar¹⁵ highlighted the advantages of a 940nm diode laser over the conventional treatment option in excision of oral Pyogenic Granuloma. Moreover, a diode laser with 810-980nm wavelengths has been used for soft tissue cutting in young patients.⁶ In children, the benefits of lasers in removal of soft tissue lesions include no need for anesthesia, which reduces the child's apprehension, and less hemorrhage, and postsurgical discomfort.

The application of a 940nm diode laser in the present case presented the best treatment option to reduce the risk of postoperative infection and impaired healing. This finding is in correlation with numerous studies demonstrating that the laser creates locally sterile conditions, which would result in the decreased bacteremia concomitant to the operation due to the bactericidal effect of laser energy.^{6,14,15}

It has been observed that, in gingival excisions, lasers tend to decrease the need for sutures and reduce bleeding quantities, whereas increasing working comfort.¹⁶ Powell *et al*¹⁷ demonstrated that use of laser for Pyogenic granuloma excisions has a lower bleeding risk and is associated with a higher coagulation rate as compared with other conventional techniques. Rai *et al.*¹⁸ shown that a diode laser could be a good treatment option for intraoral Pyogenic Granuloma due to its advantages such as ease of working and decreased recurrence rate. They utilized 808 diode laser with an output energy of 0.1-7.0 W for the successful removal of Pyogenic granuloma. Mavrogiannis *et al.*¹⁹ found that the recurrence rate with laser gingivectomy was less when compared with the conventional gingivectomy.

Being less invasive and sutureless procedure, diode laser therapy is associated with rapid healing and minimal postoperative pain. Need for post-surgical dressing is reduced and improved haemostasis and coagulation are seen with diode laser therapy. It also has role in destruction of many infectious micro-organisms. Its use has been associated with reduced post-operative discomfort, oedema, scarring and shrinkage.²⁰

While treating such lesions, importance should be given on maintaining oral hygiene. Incomplete excision is generally a commonest cause for its recurrence. Failure to remove etiologic factors and reinjury of the area are also the other factors resulting in recurrence. Studies have been demonstrated that among the lesions of oral mucosal sites, gingival lesions show a much higher recurrence rate.²¹

Conclusion

Pyogenic granuloma is a non-specific, hyperplastic, conditioned gingival enlargement. Always the diagnosis should be made with clinical and histopathological findings.

The laser therapy is a successful treatment option for this kind of lesion with no recurrence.

Source of funding

None.

Conflict of interest

None.

References

- Hullihen SP. Case of aneurism by anastomosis of the superior maxillae. *Am J Dent Sci* 1844;4(3):160-2.
- Regezi JA, Sciubba JJ, Jordan RC. Oral Pathology and Clinical Pathological Considerations. 4th ed. Philadelphia, PA: W B Saunders; 2003:115-6.
- Ganesan A, Kumar NG, Azariah E, Asokan GS. Oral pyogenic granuloma: a case report and a comprehensive review. *SRM J Res Dent Sci* 2015;6:250-6.
- Mahajan A, Singhal P, Poonam. Lobular capillary hemangioma in a child: a case report and literature review. *Open Access Sci Rep* 2012;1:265. doi:10.4172/scientificreports.265
- Jaferzadeh H, Sanadkhani M, Mohtasham M. Oral pyogenic granuloma: A review. *J Oral Sci* 2006;48:167-75.
- Asnaashari M, Mehdipour M, Moradi Abbasabadi F, Azari-Marhabi S. Expedited removal of pyogenic granuloma by diode laser in a pediatric patient. *J Lasers Med Sci* 2015;6:40-4.
- Iyer VH, Sasikumar R. Management of oral pyogenic granuloma with 940 nm diode laser: a rare case report. *Int J Laser Dent* 2013;3:100-04.
- Akbulut N, Kursun ES, Tumer MK, Kamburoglu K, Gulsen U. Is the 810-nm diode laser the best choice in oral soft tissue therapy? *Eur J Dent* 2013;7:207-11.
- Shafer WG, Hynes MK, Levy HM. Shafer's textbook of Oral Pathology. 4th edn, Philadelphia, London, Toronto: WB Saunders; 1983
- Saravana GH. Oral pyogenic granuloma: a review of 137 cases. *Br J Oral Maxillofac Surg* 2009;47(4):318-319
- Neville BW, Damm DD, Allen CM, Bouquot JE. Oral and Maxillofacial Pathology. 2nd ed. Philadelphia, PA: Saunders; 2002:437-95
- Parajuli R, Maharjan S. Unusual presentation of oral pyogenic granulomas: a review of two cases. *Clin Case Rep* 2018;6(4):690-3.
- Kirschner RE, Low DW. Treatment of pyogenic granuloma by shave excision and laser photocoagulation. *Plast Reconstr Surg* 1999;104:1346-69.
- Azma E, Safavi N. Diode laser application in soft tissue oral surgery. *Med Sci* 2013;4:206-11.
- Iyer VH, Sasikumar R. Management of oral pyogenic granuloma with 940 nm diode laser: a rare case report. *Int J Laser Dent* 2013;3:100-04.
- Fekrazad R, Chiniforush N. One visit providing desirable smile by laser application. *J Lasers Med Sci* 2014;5:47-50.
- Powell JL, Bailey CL, Coopland AT, Otis CN, Frank JL, Meyer I, et al. Nd: YAG laser excision of a giant gingival pyogenic granuloma of pregnancy. *Lasers Surg Med* 1994;14:178-83.
- Rai S, Kaur M, Bhatnagar P. Laser: A powerful tool for treatment of pyogenic granuloma. *J Cutan Aesthet Surg* 2011;4:144-7.
- Mavrogiannis M, Ellis JS, Seymour RA, Thomason JM. The efficacy of three different surgical techniques in the management of drug-induced gingival overgrowth. *J Clin Periodontol* 2006;33:677-82.

20. Angelopoulos AP. Pyogenic granuloma of the oral cavity: Statistical analysis of its clinical features. *J Oral Surg* 1971; 29:840-7.
21. Rosa CG, Lay AC, Torre ACL. Oral pyogenic granuloma diagnosis and treatment: a series of cases. *Rev Odontol Mex* 2017;21(4):244-52.

How to cite the article: Sharma P, Mohan P, Vaish S, Sharma N. Conservative management of oral pyogenic granuloma with diode laser: A case report. *J Dent Specialities* 2019;7(2):127-31.